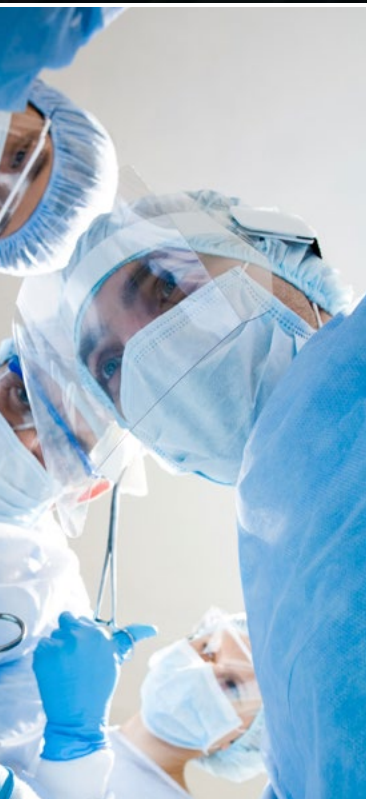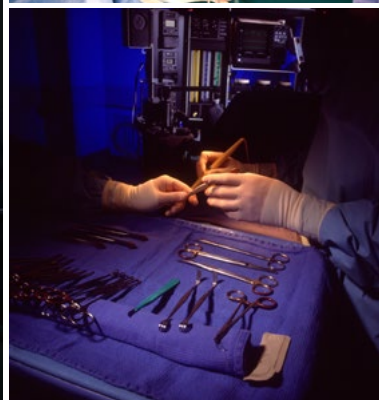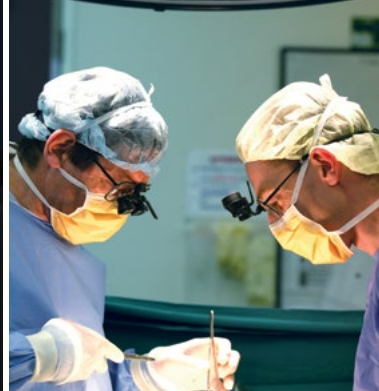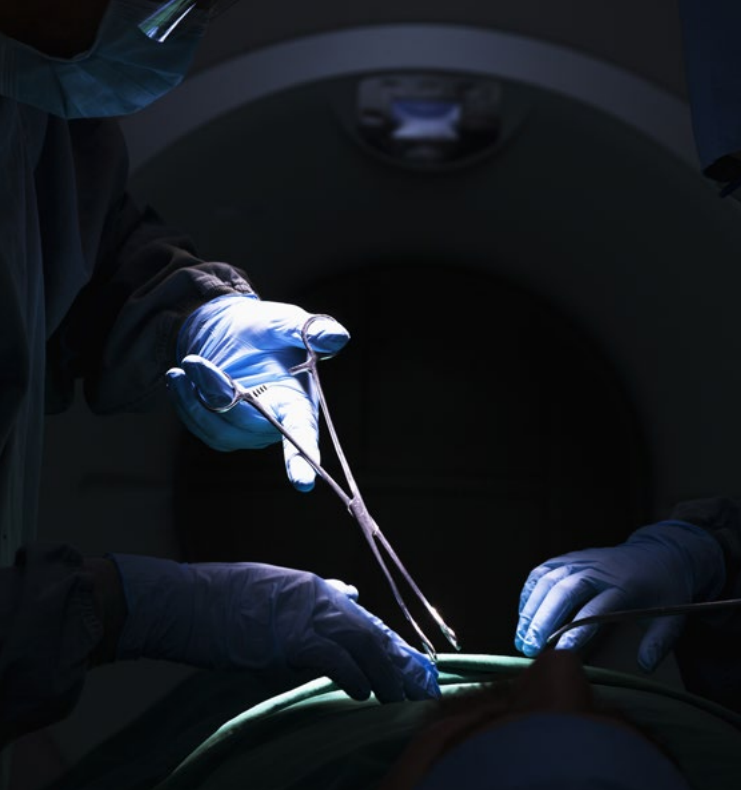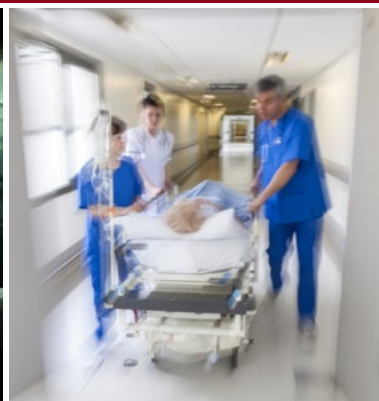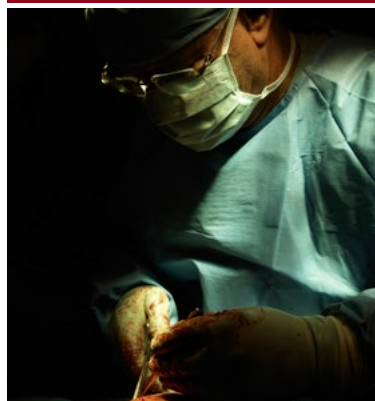


# Australian and New Zealand Audit of Surgical Mortality:

National Case Note Review Booklet

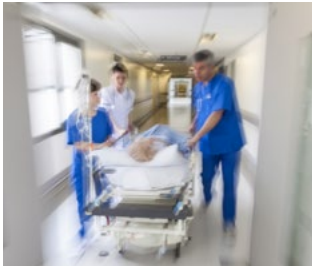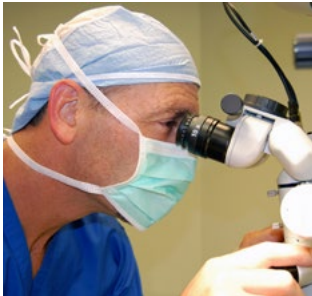**VOLUME 7 MAY 2015**





# CONTENTS

- CHAIRMAN'S REPORT .....4**
- ANZASM CLINICAL EDITOR'S REPORT .....5**
- RECOMMENDATIONS .....6**
- CASE STUDIES .....7**
  - Case study 1: Resuscitation and trauma laparotomy .....7
  - Case study 2: Closed head injury and warfarin – a lethal mix.....8
  - Case study 3a: Catastrophic vascular injury in an elective right hemicolectomy.....9
  - Case study 3b: Catastrophic vascular injury in a semi-urgent right hemicolectomy.12
  - Case study 4: Open right hemicolectomy for volvulus and low enoxaparin dosage.....14
  - Case study 5: Too much warfarin – was it even needed?.....15
  - Case study 6: Bilateral total knee replacement – think again!.....17
  - Case study 7: Delay in diagnosing bladder perforation .....18
  - Case study 8: Bleed after angiogram with inability to contact consultant.....19
  - Case study 9: Beware of ceasing anticoagulation in high embolic risk patient.....21
  - Case study 10: More aggressive DVT prophylaxis required.....22
  - Case study 11: Massive haemorrhage and coagulopathy after elective procedure .....23
  - Case study 12: Was discontinuation of antiplatelet therapy a wise move? .....24
  - Case study 13: Postoperative anticoagulation – not always possible to get it right ...25
  - Case Study 14: Inadequate preoperative reversal of anticoagulation .....27
  - Case study 15: Perioperative anticoagulation - a double-edged sword .....27
  - Case study 16: Above knee amputation – beware .....29
  - Case study 17: Fatal pulmonary embolus after delayed DVT prophylaxis .....30
  - Case study 18: The new anticoagulants...take note! .....31
- SHORTENED FORMS .....32**
- CONTACT DETAILS.....33**
- NOTES.....34**
- NOTES.....35**



DISCLAIMER: This booklet is produced for Fellows of the Royal Australasian College of Surgeons.  
Information is obtained under a quality assurance activity.

## CHAIRMAN'S REPORT

---

New medical technology brings many important advances for health care and the patients we serve, but also new challenges and problems. Management of surgical bleeding is one such example. The arrival of newer agents that can reduce the risks of thrombo-embolic events without time-consuming expensive monitoring appears to be an "ideal" intervention. However, lack of reversal mechanisms makes management of urgent surgical patients potentially a lethal intervention. Careful history, medication control, bridging treatment and multi-disciplinary management are essential in such situations. This, the seventh national case note review booklet of the Australian and New Zealand Audit of Surgical Mortality (ANZASM), illustrates the problems that can impact on any surgeon and their patients and offers some observations as to the management options that are available.

I trust you find this booklet an educational opportunity and welcome any constructive feedback.



**Professor Guy Maddern**

Chair, ANZASM Steering Committee

## ANZASM CLINICAL EDITOR'S REPORT

---

The seventh booklet includes cases from all states and territories and forms part of the feedback process that is seen as essential in the quality improvement processes of the audits of surgical mortality.

A national booklet is produced to assist smaller states who do not have enough cases to produce their own booklet, and particularly to assist in the de-identification process.

The cases in this booklet are from a variety of specialties and a variety of authors. Some have been edited to focus on a few points in a complex story or to reduce the length of the report. There is variability in the writing style as the text is, in general, written by assessors and treating surgeons and not by the editor. There may be cases where readers may not entirely agree with the assessment and comments but if we have stimulated you to think about the case we have succeeded in our aim.

Most of the cases reported here have a common theme of issues relating to bleeding. Some cases demonstrate the bad effects of unsatisfactory treatment of bleeding. Other cases include over utilisation, underutilisation or simply incorrect usage of anticoagulants. The condition of thromboembolic disease and its correct prevention and treatment has a serious impact on all surgical specialities. The usage of various deep vein thrombosis (DVT) agents has increased since the first audits of surgical mortality a decade ago, but the cases in this booklet suggest that we still have lessons to learn. It is a very significant comorbidity which should not be underestimated.

As the ANZASM office is in the same building as the South Australian Audit of Perioperative Mortality (SAAPM) office, it seemed logical that the final clinical editing process would be done by the Clinical Director of SAAPM on behalf of ANZASM. I must emphasise that I did not write this booklet. The real authors are the treating surgeons, the clinical directors, and the first- and second-line assessors of the various states and territories. To the assessors and the treating surgeons we all owe a debt of gratitude as this publication would not be possible without them. Please learn from these cases.

**Glenn McCulloch**

Clinical Director, SAAPM

Clinical Editor, National Case Note Review Booklet, ANZASM

## RECOMMENDATIONS

- In complex cases there needs to be clear, demonstrable leadership in patient management. There should be regular team meetings with all disciplines involved to ensure the treatment plan is understood by all.
- Communication is one of the most essential factors in good patient care. This includes communication between surgeons and their junior staff, between disciplines, and between hospitals, particularly in relation to the transfer of critically ill patients.
- All clinicians should provide clear and relevant records. Many of the cases in this report had record keeping deficiencies.
- The surgical case form must contain good and accurate documentation. It should be completed by a team member who was involved in the care of the patient and has sufficient experience to contribute in a useful fashion to the audit process. In instances where the surgical case form is completed by a junior staff member, a consultant should check the completed form or provide advice in advance on salient points that need to be recorded.
- All clinicians should keep in mind that clinical deterioration of a patient, in the absence of a clear cause, may be related to something outside your particular specialty.
- Early recognition and prompt treatment of unexpected bleeding is essential, particularly in the elderly or critically ill patient.
- Proper DVT prophylaxis is critical in the care of acute surgical patients. Proper care includes the correct dosage, the correct drug and timely commencement of treatment.
- Consultants should be actively involved in the care of their patients, including the decision-making process. They should also be willing to obtain other opinions if something is 'not right'.

## CASE STUDIES

### CASE STUDY 1: RESUSCITATION AND TRAUMA LAPAROTOMY

#### CASE SUMMARY

A teenager presented to hospital following a road traffic accident. It was reported that they were a pedestrian that had been hit by a vehicle travelling at approximately 80 kilometres per hour. Ambulance service personnel reported that the patient had a cardiac arrest at the scene but that spontaneous circulation had returned.

On arrival at the emergency department (ED however, the patient had a Glasgow Coma Scale (GCS) of 3, bilateral fixed and dilated pupils, no recordable blood pressure (BP) and no palpable pulse. Cardiopulmonary resuscitation (CPR) was commenced and adrenaline was given. The patient was intubated and further intravenous catheter access was obtained. Over the following hour the patient had three further episodes of arrest which were treated with CPR and inotropes, resulting in a return of spontaneous circulation. Bilateral chest drains were placed, an arterial line was inserted, and the patient underwent a focussed assessment with sonography in trauma scan.

In the early hours of the morning, an hour and a half after the patient's presentation, a laparotomy was performed. The timing of the decision to perform the laparotomy is unclear,

and while the procedure was originally discussed with the on-call surgical consultant, the procedure was performed by the surgical registrar. During the procedure it was found that the patient had a liver laceration and a retroperitoneal haematoma. It was concluded that the haematoma was either due to an inferior vena cava injury, in which case it would be incompatible with life, or a renal injury that may respond to correction of the patient's coagulopathy. The procedure however, was terminated and the patient taken to the intensive care unit (ICU) for palliation. The patient subsequently passed away.

There is no indication in the notes as to whether the surgical consultant on call was involved in the decision to terminate the procedure.

#### CLINICAL LESSONS

This case highlights the need for early recognition and early surgical intervention in the actively bleeding patient. The use of large quantities of inotropes in a young trauma patient suggests that there was failure to recognise that severe hypovolaemia was the cause of this patient's arrest. Under these circumstances there would be little benefit from the use of inotropes.

While the one and a half hour delay between the patient's arrival and operation was not necessarily excessive, it is significant in an actively bleeding patient. Procedures that

may have delayed the patient being transferred to theatre include:

- placement of an arterial line;
- the FAST scan;
- an adrenaline infusion;
- placement of bilateral chest drains.

Several of the procedures associated with the delay could have been performed in theatre while the laparotomy was proceeding.

A second issue arising from this case is that although the on-call consultant was involved in the decision to operate they did not attend the procedure. Due to the emergent nature of the procedure the most experienced person available should have performed the procedure. Attendance by the on-call consultant would also have facilitated decision-making during the operation. While the outcome for this patient was largely determined by their clinical state at the scene of the accident, there were a number of issues arising from this case. In particular, the use of large quantities of inotropes in the resuscitation of a trauma patient, the level of experience of the operating surgeon, and the appropriateness of performing procedures in the ED that delayed the patient's transfer to theatre. The degree to which inotropes were used in treating this patient suggests that consideration should be given to reviewing the hospital's resuscitation protocols in line with recent evidence.

## **CASE STUDY 2: CLOSED HEAD INJURY AND WARFARIN – A LETHAL MIX**

### **CASE SUMMARY**

A person in their 50s attended the ED of a regional hospital having experienced a fall approximately 4 hours earlier (possibly while intoxicated). The patient had a laceration on the occipital region of the scalp and was complaining of generalised headache. The patient was fully conscious at the time of assessment although there was no record as to whether there had been any loss of consciousness at the time of the original incident. The patient had a past history of alcoholism and was taking warfarin for atrial fibrillation (AF).

The scalp wound was sutured and the patient allowed to go home, but then returned 3 hours later with worsening headache and vomiting. He apparently had no neurological signs although there is no record of any assessments being performed (such as the Glasgow Coma Scale (GCS)). The patient was admitted and observed overnight. Routine four-hourly pulse and BP recordings were taken but the record does not show any neurological observations. No x-rays or computed tomography (CT) scans were performed.

The next morning the patient was found to be unconscious, with minimal response to pain. A CT scan was performed that showed a right subdural haematoma and bifrontal haemorrhagic contusions. This scan

occurred approximately 24 hours after the injury and 12 hours after admission.

Transfer was arranged by air ambulance to a tertiary neurosurgical centre. For reasons that are not apparent the transfer did not take place until 6 hours later. When assessed at the tertiary centre the patient had fixed, dilated pupils and was deemed irretrievable and died shortly after.

### **CLINICAL LESSONS**

There are three lessons to be learned from this case.

Patients on warfarin are at greater risk of developing intracranial haemorrhage and there must be a high index of suspicion of this complication. CT scans should be performed based on even a low level of symptoms. In this case, the headache and vomiting experienced by the patient should have indicated that a CT scan was required.

Standard ward observations are totally inadequate for patients who are under observation for a closed head injury. Hourly neurological observations are the minimum requirement.

A patient with an acute or subacute subdural haematoma requires urgent transfer and treatment should the admitting hospital not have the appropriate facilities. While it is possible that other demands on the ambulance service prevented rapid transfer, the 6-hour delay experienced by this patient constituted poor treatment.

## **CASE STUDY 3a: CATASTROPHIC VASCULAR INJURY IN AN ELECTIVE RIGHT HEMICOLECTOMY**

### **CASE SUMMARY**

A patient in their early 50s was noted to have iron deficiency anaemia while awaiting adjuvant chemotherapy following surgical excision of a breast cancer. A colonoscopy demonstrated a right colon cancer although recent imaging for staging the breast cancer did not demonstrate any metastatic disease.

The patient was admitted for an elective right hemicolectomy to a hospital in a regional city. During the procedure there was bleeding from an aberrant vessel located behind the duodenum. This was packed and the bleeding reportedly ceased. An ileocolic anastomosis was undertaken but required revision due to twisting of the ileal end. The patient subsequently experienced further bleeding of over 1 litre, and the notes indicate that it was most probably from a small branch of the superior mesenteric vein (SMV). It was not reported whether this was the same site as the earlier bleeding. The bowel was noted to be congested but was definitely considered viable. The first operation commenced at approximately 1000 and was completed at approximately 1200.

While the patient was in recovery there was clinical evidence of ongoing bleeding and the patient was returned to theatre. The second operation commenced at 1335 and was completed at approximately 1530. The patient was

reoperated on by the original general surgeon and a second general surgeon. At the second operation bleeding from, and loss of length of, the SMV was identified. It was felt that this was nonreconstructable in the local setting by either of the two operating surgeons or any other local surgeon. A decision was made to ligate the vein for haemorrhage control and subsequently transfer the patient to a tertiary hospital, located over 600 kilometres away, for vascular reconstruction. This was discussed with the tertiary hospital vascular surgeons.

The patient's intraoperative international normalised ratio (INR) was 1.5. It appears that fresh frozen plasma (FFP) and platelets were infused at the same time as the INR and platelet count specimen was collected. The patient was transferred to the local hospital's ICU on inotropic support at 1500. The patient's arterial pH was 7.16 with a base excess of -15, but there was no temperature recording. During the patient's stay in the ICU there was persistently profound metabolic acidosis and blood product requirement (packed red cell and FFP).

The patient was transferred via aeromedical retrieval at 1845, arriving at the tertiary hospital at approximately 2240. The patient underwent a third operation in the tertiary hospital at 2300, approximately 11 to 12 hours after the original operation and over 8 hours from the decision to transfer. At the third operation, ischaemic infarction of the entire small bowel from the

duodeno-jejunal flexure to ileocolic anastomosis was identified, and this was consistent with arterial ischaemia. This was deemed non-survivable and the patient died a few hours later. The patient's death was referred to the coroner, although no coronial autopsy report was available.

### CLINICAL LESSONS

The cause of this patient's death is not definitively known. It may have been venous injury, arterial injury or both. The notes from the tertiary hospital state that multiple sutures were present at the base of the transverse mesocolon. The main SMV trunk is usually only formed just below the neck of the pancreas by the union of a major ileal and jejunal tributaries just above where the middle colic vein enters the SMV and just above the base of the transverse mesocolon. It may be possible that the recorded SMV injury was not to the main SMV trunk, but to the major ileal tributary of the SMV proximal to the main jejunal tributary. Another possible cause of the bowel ischaemia was superior mesenteric artery (SMA) injury or ligation.

Irrespective of whether the injury was to the SMV or SMA, the aim of intervention was haemostasis, restoration of adequate arterial inflow and venous outflow, resection of nonviable bowel, and eventual restoration of gastrointestinal continuity. The likelihood of this patient surviving was low once acidosis, hypotension and coagulopathy had

developed. Recognition of the injury and intervention during the first operation would have increased the patient's chances of survival. By the time the injury was recognised at the second operation it was unlikely that the patient could have survived. Rapid intervention at this point was the patient's only chance for survival, and this was not possible due to the need for transfer.

The major concerns associated with this case related to cause and prevention, recognition, and management of major abdominal vascular injuries. The SMV is thin walled and easily torn, especially during rushed attempts to control haemorrhage, and this can lead to catastrophic and difficult to control haemorrhage as seen in this case. It is not uncommon to have bleeding during mobilisation of the right colon from the area in front of the pancreas and duodenum, but catastrophic haemorrhage from SMV or SMA injuries is rare. Careful dissection in this area is essential to prevent such injuries, particularly if the tumour has involved middle colic nodes or has invaded the mesocolon.

A search of the literature reveals only a handful of case reports related to operative injury of the SMV, and a few series of venous injuries during various abdominal operations. The low number of reports may be due to the rarity of such operative injuries as well as publication bias. Similar outcomes appear to have been found for ligation compared with

reconstruction in blunt and penetrating SMV injuries resulting from trauma. Both ligation and reconstruction of penetrating SMV injuries are associated with a high mortality rate. In a pancreaticoduodenectomy, the ligation of one of the major SMV tributaries (ileocolic or jejunal) is usually not associated with adverse outcomes. It has also been reported that ligating the main SMV trunk is not associated with ischaemia provided the head of pancreas and pancreaticoduodenal veins are left intact.

The dearth of reports in the literature means that it is not possible to provide specific advice regarding surgical techniques that best prevent or manage these injuries. It should be recognised, however, that careful dissection, early recognition of problems and attention to the principle of inflow and outflow restoration will provide the patient with the best chance of survival.

The failure to recognise the injury during the first operation is of concern. The bowel was reportedly dusky but viable. A dusky bowel following a right hemicolectomy is not normal and should have prompted the surgeon to consider a vascular injury, particularly given the bleeding at the base of the transverse mesocolon. There was, however, no capacity to repair such an injury without transferring the patient to a second hospital. At this point the patient was almost certainly not going to survive.

*Additional comments relating to this case appear under case study 3b.*

## CASE STUDY 3b: CATASTROPHIC VASCULAR INJURY IN AN SEMI-URGENT RIGHT HEMICOLECTOMY

### CASE SUMMARY

This person in their 70s presented at a regional hospital with a history of abdominal pain for 3 days, vomiting for 24 hours and had not passed flatus for 3 days. The patient had not undergone any prior abdominal operations but had received radiotherapy for prostatic carcinoma. The abdomen was soft but distended. The clinical diagnosis was small bowel obstruction and a CT scan showed a caecal mass.

The patient underwent a semi-urgent right hemicolectomy which revealed an obstructing caecal cancer. As the surgeon was completing during the operation the patient experienced significant bleeding from the SMV area medial to the duodenum. The bleeding was difficult to control intraoperatively. Following discussion with a metropolitan hospital the decision was taken to transfer the patient. The surgeon in the regional hospital placed vascular clamps on the bleeding areas and a vascular surgeon was on standby at the metropolitan hospital.

While the request was for an immediate air transfer there was a delay of approximately 4 hours in stabilising and transferring the patient. The patient was haemodynamically unstable during the flight.

On arrival at the metropolitan hospital the patient was transferred immediately to the operating theatre where general

surgical and vascular teams were waiting. During the laparotomy the clamps on the SMV and tributaries were removed while ligation with suture was performed. The combined surgical teams could not salvage the SMV as a 5 cm section was shredded, and so it was ligated. The removal of the temporary vascular clamps resulted in an immediate improvement in the appearance of the small bowel, which had severe venous congestion and threatened infarction. The patient had a short run of arrhythmia from reperfusion injury and this required a short period of CPR.

The patient had already lost a significant amount of blood, and was coagulopathic and acidotic. The decision was made to perform a damage-control laparotomy, as most of the small bowel had venous ischaemia or congestion, and only 1 metre of proximal jejunum was healthy. There was ongoing ooze from the retroperitoneal area. A decision was made to have a relook laparotomy with possible small bowel resection.

The patient was transferred to the ICU where he required high doses of inotropes and remained acidotic despite all available treatment. He continued to have slow bleeding from drains, and since being transferred had received three to four massive transfusion packs. The patient's lactate levels were rising, indicative of bowel ischaemia. Treating staff in the ICU did not believe that they could improve his condition and the patient was going into multiorgan failure.

A discussion was held with the family outlining the patient's poor prognosis. A relook laparotomy was offered on the understanding that the prognosis for the patient was still poor, as most of the small bowel may have to be removed leading to short bowel syndrome. The family agreed to withdraw treatment and the patient passed away.

### CLINICAL LESSONS

The findings of the second operation at the metropolitan hospital clearly show that the SMV was damaged during the procedure. It appears to have been a traction injury rather than a direct injury during dissection. This is a rare event. The regional surgeon was correct in arranging for patient to be transferred once it became apparent that the complication required the attention of a specialist in this area.

The delay in transfer certainly lessened the chances of a good outcome. By the time the patient went to theatre in the metropolitan hospital their fate was sealed, as they were acidotic, coagulopathic and had rising lactate levels.

### COMMENTS ON CASE STUDIES 3a & 3b.

These two cases were remarkably similar and the following comments relate to both cases.

1. The two cases serve as a reminder that catastrophic outcomes can result from abdominal vascular injuries. This is applicable to all surgeons performing abdominal surgery, including right hemicolectomy.

2. Care with dissection/retraction at the base of the transverse mesocolon is presumed to be essential to minimise this risk; a surgeon or hospital performing such operations should have adequate knowledge and skills to recognize and manage these severe intraoperative complications.
3. After bleeding from around the SMV is controlled the SMA pulse should be checked and documented. Clinical editor's comment: this comment was made as in one case there was no record of the presence or absence of a SMA pulse.
4. Surgeons practicing in regional cities, or who do not otherwise have the support of a vascular surgeon, should consider refreshing their vascular surgical skills. This would be of benefit in uncommon scenarios, such as with these two cases, as well as in managing trauma cases.
5. In both cases there was a significant delay in transfer. This delay may have been a critical factor in the poor outcome for both patients.

### REFERENCE

The following article is highly pertinent to these cases, and is likely to be of value to all surgeons involved in abdominal surgery:  
*Asensio JA, Petrone P, Garcia-Nuñez L, Healy M, Martin M, Kuncir E. Superior mesenteric venous injuries: to ligate or to repair remains the question. J Trauma. 2007 Mar;62(3):668-75.*

“Superior mesenteric vein injuries are rare and incur high mortality. Given their low incidence, little data exist delineating indications for when to institute primary repair versus ligation. The purposes of this study are to review our institutional experience....to examine and define the indications and outcomes for primary repair versus ligation.

Retrospective 156 months study (January 1992 through December 2004) in a large Level I urban trauma center of all patients admitted with superior mesenteric vein injuries. Patients were stratified, according to surgical technique employed to deal with their injuries, into those undergoing primary repair versus ligation to determine outcomes and define the surgical indications of these methods.

There were 51 patients with a mean Injury Severity Score of  $25 \pm 12$ . Mechanism of injury was penetrating for 38 (76%), blunt for 13 (24%), and patients undergoing ED thoracotomy for 4 (8%). Surgical management was ligation for 30 (59%), primary repair for 16 (31%), and 5 (10%) patients were exsanguinated before repair. The overall survival rate was 24/50 (47%). ..... The survival rates of patients with superior mesenteric vein and superior mesenteric artery was 55% and superior mesenteric vein and portal vein (PV) was 40%. **The survival rate of patients with isolated superior mesenteric vein injuries was 55%.**

Conclusions: SMV injuries are highly lethal. Multiple associated vessel

injuries increase mortality. Mortality correlates well with the American Association for the Surgery of Trauma-Organ Injury Scale for abdominal vascular injuries. Patients undergoing primary repair have higher survival rates (63%) and lesser numbers of associated vascular and nonvascular injuries; whereas those undergoing ligation have a smaller survival rate (40%) and higher number of associated vascular and nonvascular injuries. Ligation appears to be safe and should be selected for hemodynamically unstable patients with a large number of associated injuries”.

#### **CASE STUDY 4: OPEN RIGHT HEMICOLECTOMY FOR VOLVULUS AND LOW ENOXAPARIN DOSAGE**

##### **CASE SUMMARY**

The patient, in his early 70s, was admitted with abdominal pain and distension. The pain and distension was caused by a caecal volvulus that was confirmed by two CT scans. The patient was on warfarin for a previous massive pulmonary embolism (PE) and suffered from severe chronic obstructive pulmonary disease, using oxygen at home.

There was a delay in this patient's treatment as the ICU consultant did not agree to admit the patient until the following day. A right hemicolectomy was performed with direct anastomosis without protective ileostomy. The patient appears to have had an uneventful recovery

from the procedure, but passed away suddenly from what appears to have been a PE. The patient had in place a no-resuscitation order in the event of a cardiac arrest. A postmortem examination was not performed.

##### **CLINICAL LESSONS**

There are a number of questions or issues arising from this case. The first is whether the consultant surgeon was actively involved in discussing the patient with the ICU consultant. The notes do not indicate the level of involvement of the consultant surgeon. This notwithstanding, surgery for this patient should not have been delayed as abdominal distension prevents correct breathing.

A second issue relates to postoperative anticoagulation. The first dose of enoxaparin seems to have been given 3 days after surgery at a single dose of 40 mg. This is a small dose considering that the patient was on warfarin prior to admission, and was efficiently anticoagulated with an admission INR of 4.8. Anticoagulation should have started just after surgery to ensure that the patient quickly reached a hypocoagulation level equivalent to that prior to surgery.

Correct administration of enoxaparin would have involved two doses per day, and for a 60 kg patient the dosage should have been 60 mg twice a day. There is nothing in the ICU nursing report to indicate that the patient had any signs of bleeding, such as under dressings or in catheter sites or the nasogastric tube. Despite the patient's

slow progress, and with no sign of any surgical complication, the dose of enoxaparin was not increased.

Warfarin was initiated at a dose of 3 mg while the patient was not eating well and was likely to have poor absorption. This dose was lower than the usual 5 mg dose, and at 10 days postoperatively the patient had an INR of 2.3. In effect, compared to their condition prior to admission, this patient was not anticoagulated for 10 days.

While the surgical procedure was successful, this patient was exhausted and unable to take and absorb an adequate oral intake. This meant that he was unfit to benefit from the warfarin treatment provided. Enoxaparin should have been given at a correct and efficient dose until the patient was more mobile and eating well without vomiting. It should be recognised, however, that the patient's chest condition required that he be kept on the dry side (no fluid overload) and this may have provoked venous clotting despite the use of thromboembolic deterrent stockings.

#### **CASE STUDY 5: TOO MUCH WARFARIN – WAS IT EVEN NEEDED?**

##### **CASE SUMMARY**

A person in their mid-70s presented with a large per rectum bleed. The patient had significant comorbidities including chronic renal failure and chronic obstructive pulmonary disease that required home oxygen.



She had commenced taking warfarin for a supposed DVT two weeks prior to presentation.

At admission the patient's haemoglobin was 5.3 and INR was 6.2. They were resuscitated with blood products and the INR was reversed. The patient was taken for an emergency gastroscopy that revealed no upper gastrointestinal tract cause for the bleed. They remained stable over the next 4 days in hospital, with stable haemoglobin and no further bleeds, and was discharged with a plan for a colonoscopy in 6 weeks. The patient died 8 days after discharge and the cause of death was unknown.

### CLINICAL LESSONS

This case was difficult to fully assess given that the cause of death remains unknown. Concerns were raised by the first-line assessor regarding a lack of investigations at the time of the patient's initial presentation, such as angiography, labelled scan and colonoscopy. Despite these concerns it is likely that the surgical management was sound. Angiography would have been difficult given the patient's cardiac risk factors, making the use of contrast difficult, and nuclear medicine may not have been available at the hospital. Either way, these investigations give a poor yield once the bleeding has stopped, as it did rapidly in this case once the INR was reversed.

Colonoscopy in the immediate post-bleed setting, and without adequate preparation, also gives poor results. Care with the bowel preparation would have been required given

the patient's renal function. It is questionable whether a colonoscopy would have provided a practical clinical benefit. Conservative treatment would have been provided had the patient been found to have DVT they would have been considered a good candidate for a colectomy.

The main area of concern relates to the question of why the patient was on warfarin in the first place. It was allegedly for a left leg vein DVT but the venous duplex of the left leg was completely normal. If this was a misinterpretation of the results it would constitute an adverse event not associated with the audited surgical team. The surgical team did restart the patient on warfarin after the per rectum bleeding had stopped, perhaps also working under the assumption that the patient had previously had a DVT. Either way, this case reinforces the lack of thought that goes into commencing elderly patients on warfarin when there is very little or even no hard evidence for doing so.

This patient may not have died directly as a result of her warfarin therapy. It will, however, certainly not have helped that she had been over-warfarinised, and suffered a massive rectal bleed as a result, just 13 days prior to her death. The indications for warfarin therapy should be reviewed for any patient who attends with bleeding due to over-warfarinisation. This should include liaising with the doctor who commenced the therapy with a view to ceasing the warfarin therapy or identifying safer alternatives.

## CASE STUDY 6: BILATERAL TOTAL KNEE REPLACEMENT – THINK AGAIN!

### CASE SUMMARY

This patient was elderly, had a preoperative body mass index between 35 and 40, and suffered from osteoarthritis in both knees. The patient had also been a smoker for many years, but gave up six months prior to the intended surgery. There was a history of PE nearly a decade ago, after a hernia repair, despite active prophylaxis at that time.

After discussions with the orthopaedic surgeon the patient was offered bilateral total knee replacement (TKR) and appropriate consent was obtained. The preoperative workup seems to have been comprehensive from the medical and anaesthetic points of view. Preoperative physical therapy for lower-limb muscular strengthening and weight reduction were absent.

The surgical process and postoperative care were well within standard guidelines and appropriate DVT prophylaxis was used. Postoperative low haemoglobin was to be expected but blood loss should have been recognised and replaced earlier. Postoperative pain control was problematic and despite excellent physical therapy, mobilising the patient became a major issue. The problems encountered trying to mobilise the patient led to greater than average venous stasis.

The patient died following a sudden collapse and cardiac arrest, and a PE was considered to be the most likely diagnosis and cause of death. At autopsy it was revealed that a dilated cardiomyopathy was the most likely cause of death. The autopsy also revealed scattered marrow and fat emboli in the pulmonary vessels and mild emphysema. The patient's low haemoglobin was not only surgical blood loss but also an unrecognised perinephric haematoma which was probably related to the DVT prophylaxis.

### CLINICAL LESSONS

This patient had a significant medical history and significant comorbidities. The orthopaedic diagnosis was clear: osteoarthritis in both knees. The history of DVT was known and active prophylaxis was provided. All these facts are clear. What cannot be assessed is the level of morbidity caused by the osteoarthritis or by the comorbidities.

The absence of preoperative physical therapy also seems very inappropriate. This patient was on a waiting list for surgery for more than a year. Prehabilitation in the form of physiotherapy, hydrotherapy or both can be very cost effective in this situation. Preoperative assessment and planned weight reduction would have been appropriate but does not appear to have been considered for this patient. A mix of non-operative measures often provides substantial improvement in symptoms.

In retrospect, the decision to undertake two TKRs in one session proved imprudent. This was a heavy patient with lung damage, as well as other comorbidities of lesser importance. Performing one TKR was likely to tax postoperative mobility, while performing a bilateral TKR replacement was always likely to create major problems. All surgeons should consider the risks very carefully before offering a patient a bilateral TKR.

## **CASE STUDY 7: DELAY IN DIAGNOSING BLADDER PERFORATION**

### **CASE SUMMARY**

A middle-aged male was diagnosed with hormone-refractory advanced metastatic prostate cancer with probable bone marrow involvement and a low platelet count. He was admitted with haematuria and clot retention, and had a haemoglobin level of 8.1 g/dL. The patient was transfused and an indwelling catheter inserted for bladder washout. He was discharged after a successful trial of void, 8 hours after the last transfusion. Three weeks prior to the admission he had undergone transurethral resection of the prostate. The patient was readmitted 3 days later with hypovolaemic shock and haematuria, and was transfused with three units of blood. Catheter bladder drainage and irrigation was performed. The bleeding continued over the next few days, requiring further transfusion and two units of FFP. He was taken to

theatre for diathermy of the prostate bed and evacuation of clots.

The following day he was thought to have had a cerebrovascular accident, having developed receptive and expressive dysphasia. Aspirin was commenced as well as heparin 500 units bd. By this stage the patient had received over 10 units of blood and two units of FFP.

The haematuria persisted and the patient was catheterised with a 14 French size (Fr) catheter by the resident, who also stopped heparin and aspirin. The catheter was changed to a 20 Fr 3-way catheter with irrigation. When this catheter blocked it was changed to a 24 Fr 3-way catheter. The patient required further transfusion. A CT cystogram showed a bladder perforation on the left, with contrast extravasation into the retroperitoneal region. The patient underwent a laparotomy during which the surgeon found a left posterolateral intraperitoneal bladder perforation and subtrigonal extension of the malignant prostate. The patient was cared for in the ICU during the postoperative period and subsequently went back to the ward. While on the ward the patient developed chest pain and shortness of breath and died soon afterwards.

### **CLINICAL LESSONS**

There were several issues associated with this case.

1. This patient had prostatic carcinoma with probable bone marrow involvement and low platelet count.

The non-contrast brain CT scan was normal and there was only clinical suspicion of an embolic event. These circumstances, combined with the patient also having been transfused with 11 units of blood and 2 units of FFP, make the treatment with aspirin and heparin less than ideal.

2. The use of a 14 Fr catheter to drain a bladder with haematuria and clot retention is not standard care and may have contributed to the bladder perforation.
3. The patient did not undergo a CT scan in the early stages of his illness to assess the cause of the persistent haematuria. This was despite the patient requiring multiple transfusions.

In summary, while the prognosis for this patient was poor there were two factors that may have contributed to the bladder perforation and ensuing surgery. Firstly, the use of aspirin and heparin on clinical suspicion of CVA would have made the haematuria worse but in the absence of radiological confirmation and secondly, the use of a 14 Fr catheter to drain a bladder with haematuria and clot retention.

## **CASE STUDY 8: BLEED AFTER ANGIOGRAM WITH INABILITY TO CONTACT CONSULTANT**

### **CASE SUMMARY**

An elderly patient had a right leg popliteal aneurysm with possible embolic complications. The patient was a non-insulin-dependent diabetic

and was hypertensive, but there was no history of ischemic heart disease or cardiac issues. There was a history of idiopathic thrombocytopenia and the patient was taking Prednisolone and Dipyridamol. On examination there were pulses present bilaterally, apart from a dorsalis pedis on the right. A palpable aneurysm was present in the right popliteal fossa.

The patient underwent a right femoral angiogram and the puncture was made in the right common femoral artery under ultrasound guidance. The angiogram revealed the presence of a popliteal aneurysm with probable embolic occlusion of the posterior tibial artery from its origin. The intention was that the patient would undergo a femoro-popliteal bypass. Groin pressure was applied to control the puncture site. Nursing observations showed that there was no change in the patient's haemodynamic condition, but it was noted that the leg appeared cool and pale despite the normal pulse and BP. Sixteen hours after the angiogram a medical emergency team (MET) call was made. The patient had become hypotensive, with a drop in BP to 70 mm systolic, and there was a mass palpable in the right lower quadrant.

The patient received a dose of Enoxaparin, although the medical and nursing notes were conflicting in terms of the dose ordered for the patient, the amount actually received by the patient and the timing of the dose.

Twenty-four hours after the angiogram the patient was diagnosed as having a

bleed into the retroperitoneal region, and this was confirmed by abdominal CT scan. The patient's haemoglobin was 9.5 and the surgical registrar had been contacted. The patient remained in the ward until being transferred to the ICU. Further Enoxaparin was withheld. The patient required intensive fluid replacement including blood transfusions, but became unresponsive and acidotic with a haemoglobin of 7.7. The patient was taken directly to theatre and the cause of the bleeding was found to be a high puncture from the angiogram and a large retroperitoneal haematoma. The haematoma was evacuated and the puncture site in the external iliac artery was repaired with a suture. Intraoperatively the patient received five units of packed cells together with other blood products.

On return to the ICU the patient was still grossly acidotic, with a pH of 7.15. The patient had not passed urine since the operation and required inotropic support to maintain BP. Twelve hours after the exploration of the femoral puncture site it was noted that patient's abdomen was distended and the wounds were oozing. The patient was probably coagulopathic. Despite the blood transfusions the haemoglobin continued to fall. An unsuccessful attempt was made to contact the vascular surgeon. Another CT scan of the abdomen was performed, revealing further right retroperitoneal haemorrhage. A further attempt to contact the vascular surgeon was again unsuccessful so another

consultant was informed. The patient's haemoglobin continued to drop despite repeat blood transfusions.

The patient underwent a repeat laparotomy. Numerous bleeding vessels in the retroperitoneal region were found and clipped, and these were thought to have been the cause of the ongoing bleeding. Two packs were placed, the abdomen closed and the patient was returned to the ICU. Over 20 units of cells had been transfused together with other blood products. While the bleeding was now controlled in the next 24 hours the patient progressively developed multiorgan failure and ongoing and worsening acidosis. It was decided that there should be no further active management and the patient died shortly thereafter.

### CLINICAL LESSONS

There were several major problems in the management of this patient. Following the angiogram it was possible that the patient was over-anticoagulated as the medical and nursing notes were conflicting in terms of the dose ordered for the patient, the amount actually received by the patient and the timing of the dose.

Secondly there appears to have been a high puncture of the femoral artery despite the use of ultrasound guidance - this was the cause of the initial bleed resulting in a MET call. It was decided that the patient should remain on the ward. This patient would have been much better managed in a high dependency or ICU setting.

Thirdly a significant issue was the inability of hospital staff to contact the vascular surgeon.

Once the retroperitoneal bleeding had been diagnosed in an anticoagulated patient, aggressive surgical repair should have been undertaken - there appears to have been a delay of 8 hours from the MET call to the first surgery. This patient died as a result of the delays in treating what potentially should have been an easily correctable complication of an angiogram.

## CASE STUDY 9: BEWARE OF CEASING ANTICOAGULATION IN HIGH EMBOLIC RISK PATIENT

### CASE SUMMARY

The patient was admitted to hospital under the care of the vascular unit with acute ischaemia of the right upper limb. The patient's history included coronary artery bypass surgery followed by AF and multiple cerebral strokes that had left the patient with weakness down the right side. The history also included significant urological bleeding that had resulted in falls and hypotension, and which had necessitated that the patient stop taking warfarin. The patient was also in hospital for investigation of the urological bleeding.

While in hospital the patient underwent brachial embolectomy. The planned urological surgery was delayed due to the patient having a high INR. All anticoagulation therapy was stopped in preparation for the procedure, and this occurred twice: at the time the

procedure was delayed and also when it finally went ahead.

The patient developed further right lower limb ischaemia following the urological surgery and embolectomy was again required.

While the patient initially progressed well there were difficulties with mobility which led to the development of a chest infection. While the chest infection was adequately treated, the patient subsequently developed a myocardial infarction and pneumonia, and this led to the patient's death.

### CLINICAL LESSONS

The case notes provided an adequate record of the patient's course in hospital for this procedure, as well as a satisfactory record of previous hospitalisations. The case notes confirmed that it was necessary to cease the warfarin due to excessive blood loss prior to admission. They also confirmed that the patient had experienced multiple cerebral infarcts prior to starting warfarin. The patient was obviously at considerable risk given the past history and comorbidities.

Review of the history shows that this patient underwent vascular surgical procedures in a timely manner and that the procedures were carried out by appropriately qualified surgeons.

It was unfortunate that the rescheduling of the planned urological surgery meant that the patient had complete cessation of their anticoagulation treatment on two occasions. There was no documentation

to indicate that the patient had been cared for in the high dependency unit (HDU). Had the patient received support in the HDU it is possible that the initial postoperative chest infection may have been recognised and treated earlier.

Areas of concern identified by the first-line assessor include the delay in surgery for urological bleeding while the patient was off all anticoagulation, and the development of the postoperative chest infection. There is no doubt that the delay led to a second embolus to the right leg, resulting in a further surgical procedure. This patient had a well-documented history of embolic events, requiring anticoagulation at all times. There is no indication that the urological unit understood the significant nature of the risk to this patient.

That the patient developed a chest infection may not have been entirely unexpected given the patient's history of multiple strokes and other comorbidities. The final event was the development of a Non-ST segment elevation myocardial infarction with a marked increase in troponin level, and subsequent pneumonia development. It was appropriate that palliative measures were undertaken at this point.

This case illustrates the problems associated with stopping anticoagulation in a patient who has had multiple embolic episodes when not anticoagulated. Complete cessation of anticoagulation is unavoidable under some circumstances, such as when significant bleeding is occurring or a

specific operative treatment is required. Surgical units and hospitals must be aware that unnecessary delays in treatment are catastrophic for patients in these circumstances. Hospitals may benefit from a method of predicting the thromboembolic risk for patients who are required to stop anticoagulation.

The postoperative course for this patient was almost inevitable given the comorbidities and necessity for multiple surgical procedures. Had the patient received a brief stay in the HDU the chest infection may have been identified earlier and treatment may have commenced prior to postoperative day four. The patient's immobility and comorbidities meant that it was going to be difficult to obtain a good outcome once the chest infection was present.

### **CASE STUDY 10: MORE AGGRESSIVE DVT PROPHYLAXIS REQUIRED**

#### **CASE SUMMARY**

A patient underwent a radical cystectomy and right nephroureterectomy with ileal conduit formation one month after having undergone a transurethral bladder tumour resection and insertion of ureteric stents. The patient was of advanced age and was considered ASA (American Society of Anesthesiologists) grade 3. Pre-existing comorbidities included ischaemic heart disease and renal impairment.

The resection and ureteric stent insertion was performed in a

private hospital and was covered by subcutaneous heparin for around 3 days. Following the procedure the patient had difficulty walking, although the reason for this was not documented. The patient did not leave hospital between the time of the resection and the cystectomy, and it is unclear whether the patient received ongoing heparin during that time.

In the second hospital the patient underwent a radical cystectomy and right nephroureterectomy with ileal conduit formation. The resident medical officer's admission notes from the day before the cystectomy state that the patient had a past history of DVT and PE. This history was not recorded by the preadmission clinic or by the consultant anaesthetist at the same clinic. It was also not recorded on the surgeon's admission and consent form. The patient received an average dose of subcutaneous heparin the night before the cystectomy but did not receive heparin on the day of surgery. Calf compressions were used during the operation and for 24 hours postoperatively. Thereafter the patient wore thromboembolic deterrent stockings and received a further average dose of subcutaneous heparin twice daily.

Postoperatively the patient had a prolonged ileus and required total parenteral nutrition support. The physiotherapists had considerable problems mobilising the patient and this was partly due to the patient's clinical condition. Nearly two weeks

after the radical cystectomy the patient suddenly collapsed and died. It was assumed that the patient's death was the result of a PE.

#### **CLINICAL LESSONS**

This patient had at least a moderate risk of perioperative death, being of advanced age and with serious comorbidities.

Despite the patient being at risk of developing DVT or PE they did not receive heparin on the day of surgery. The rationale for this was not provided, yet these doses on the day of surgery are arguably the most important. Consideration could have been given to more aggressive prophylaxis (for example, Clexane 40 mg subcutaneous daily or an even higher dose) in both the preoperative and postoperative periods.

### **CASE STUDY 11: MASSIVE HAEMORRHAGE AND COAGULOPATHY AFTER ELECTIVE PROCEDURE**

#### **CASE SUMMARY**

The middle-aged patient had an elective laparoscopic cholecystectomy in a regional hospital for symptomatic cholelithiasis. The patient had previously been on warfarin for AF.

The operation itself was uneventful. The patient received warfarin on the day of and following surgery. A high dosage of Clexane was also given to the patient. Following the operation the patient suffered significant internal bleeding into the peritoneum, diagnosed at a subsequent laparotomy.

Despite treatment with fluid and blood replacement, the patient remained unstable, hypotensive, anuric, acidotic and coagulopathic, and was transferred to a tertiary hospital.

A repeat laparotomy was performed several days later, resulting in a diagnosis of repeat haemorrhage. The patient was in a moribund condition and died shortly after.

### CLINICAL LESSONS

The combination of warfarin and high dose Clexane was responsible for the initial bleeding. The patient's severe ongoing coagulopathy, and the failure of both medical and surgical interventions to address the condition, were unpredictable in this situation. Consideration should, however, be given to the timing and quantity of anticoagulant medications used following the elective procedure.

## CASE STUDY 12: WAS DISCONTINUATION OF ANTIPLATELET THERAPY A WISE MOVE?

### CASE SUMMARY

An elderly patient was admitted to a large private hospital for elective left knee replacement surgery. The patient had undergone a successful right knee replacement eight years previously.

The patient's significant medical history included coronary stenting, which had been performed several years earlier. The patient had also had a short admission for a transient ischaemic

attack/cerebrovascular accident three months prior to the current episode. The patient's usual medications included Asasantin, a statin and an antihypertensive, and the patient was instructed to cease the Asasantin one week prior to surgery. This decision was apparently reached after consultation with a general physician and the treating cardiologist, although there was no confirmation of this in the documentation from the surgeon or either specialist.

The patient was admitted on the morning of surgery and, as per the surgeon's standard protocol, an electrocardiogram and laboratory tests were undertaken. The anaesthetist made an annotation on the anaesthetic record that both the physician and the cardiologist had cleared the patient for surgery. An uneventful routine tricompartmental knee replacement was performed under general anaesthetic with supplementary femoral nerve blockade. The patient remained stable while in the recovery room and was transferred back to the orthopaedic ward. The ward nursing staff recorded several sets of normal observations and the patient appeared to be making an uneventful recovery. Clexane 20 mg and Asasantin were given late that evening.

Shortly after midnight the patient was found unresponsive. The patient was found to be in ventricular fibrillation with cardiogenic shock, and was intubated and ventilated. A prolonged period of resuscitation ensued. The

patient was transferred to the ICU and was subsequently found to have sustained a massive anterior acute myocardial infarction with resultant hypoxic brain damage. The patient progressively deteriorated over the next 48 hours and a decision was made to withdraw support. The patient died 72 hours after the surgical procedure.

### CLINICAL LESSONS

Given the patient's vascular disease there was significant risk associated with any major surgery. There are, however, two areas that are either for consideration or perhaps of concern.

Firstly, the merit of undertaking an elective TKR just a few months after the patient was hospitalised due to a cerebrovascular event. There was no information in the hospital notes outlining the nature or severity of the cerebral event. There was also no evidence of any investigations aimed at determining whether an elective TKR could be performed for this patient with an acceptable level of risk.

Secondly, given the circumstances it was surprising that Asasantin was temporarily stopped so soon after the patient had experienced a cerebral event. A more cautious approach would have been to delay the TKR, or for the patient to have continued taking the antiplatelet agent.

The important issue arising from this case was the decision to discontinue the antiplatelet therapy. The theoretical (but unproven) benefit of withholding antiplatelet medication prior to TKR

must be balanced against the real (proven) benefits of perioperative maintenance of antiplatelet medications in patients with coronary stents and carotid artery disease. The evidence strongly suggests that the decision to withhold Asasantin was incorrect, and the fact that the decision was made in conjunction with other specialists does not ameliorate this.

## CASE STUDY 13: POSTOPERATIVE ANTICOAGULATION – NOT ALWAYS POSSIBLE TO GET IT RIGHT

### CASE SUMMARY

A very elderly nursing home resident was admitted following a mechanical fall with a left displaced subcapital fractured neck of femur. The patient was on warfarin for AF and had an INR of 2.1 on admission. The past medical history included a previous cerebrovascular accident and hypertension. Vitamin K was given on admission and the standard neck of femur pathway process instigated. A femoral nerve catheter was inserted by the anaesthetic team to provide pain relief.

The following day a cemented Exeter hemiarthroplasty was carried out via a Hardinge anterolateral approach. The surgery was uneventful from an orthopaedic point of view, but the patient was noted to have ECG changes and intraoperative monitoring changes consistent with an ST elevation myocardial infarction (STEMI). The patient was discussed

with the cardiology team and a decision was made, involving consultation with the surgeons, anaesthetist and cardiologists, to commence aspirin and intravenous heparin immediately following surgery. Clopidogrel was withheld at that stage due to the already increased risk of bleeding associated with the administration of aspirin and heparin.

The patient continued to have wound ooze in the first 12 days after surgery, and was taken to theatre on postoperative day 12 for a haematoma washout. The microbiology samples from theatre at this stage grew *Staphylococcus epidermidis*, *Staphylococcus capitis* and *Enterococcus faecalis*. Eight days following the initial washout the patient was taken to theatre for a first stage revision and insertion of an antibiotic-impregnated cement spacer. The patient continued to deteriorate over the following 6 days despite full active management, and developed signs and radiology in keeping with some form of abdominal perforation. In liaison with the general surgery team the decision was taken to manage the patient conservatively. The patient died 26 days after the initial procedure, with perforated duodenum listed as the cause of death.

### CLINICAL LESSONS

A cemented hemiarthroplasty in a very elderly patient is a very high risk procedure. In this case the patient developed a substantial haematoma that subsequently became infected, necessitating two further visits to

theatre. The physiological stress associated with the haematoma, and return visits to theatre, is likely to have contributed significantly to the patient's duodenum perforation and subsequent death.

There was good evidence that the patient had experienced an intraoperative STEMI and this was recognised by the anaesthetic team. The on-call cardiology team was involved promptly and appropriately, and the treatment for the STEMI recommended by the cardiology team was a combination of aspirin, clopidogrel and heparin. This combination of medical treatment is ideally instigated as soon as possible after the diagnosis of a myocardial infarction. However, in this case there were two competing priorities in the immediate postoperative period: protect the patient from ongoing myocardial infarction and prevent excessive postoperative bleeding and haematoma formation.

There was no right or wrong decision in terms of commencing anticoagulation therapy. The key point is that the decision was made at a senior level between surgeon, anaesthetist and cardiologist. Withholding of the clopidogrel was a sensible compromise. Overall, this was a measured and carefully considered response to a difficult situation. It should also be acknowledged that the record keeping in this case was very thorough.

## CASE STUDY 14: INADEQUATE PREOPERATIVE REVERSAL OF ANTICOAGULATION

### CASE SUMMARY

A very elderly patient was admitted with acute acalculous cholecystitis. The patient had significant comorbidities and was on anticoagulation therapy. Conservative management of the patient was unsuccessful and the patient underwent surgery four days after admission. Vitamin K was given preoperatively. A laparoscopic cholecystectomy was initially attempted however bleeding necessitated a conversion to open surgery. The patient died postoperatively due to haemorrhagic shock.

### CLINICAL LESSONS

There were some aspects of this patient's care which could have been different, including the timing of the decision to operate, and the degree to which the anticoagulation had been reversed prior to surgery. However, it is unlikely that changes in either area would have affected the patient's outcome.

On admission the patient's white blood cell count was  $24.6 \times 10^9/L$  and C-reactive protein was 263 nmol/L. Values at this level raise the possibility of either gangrene or empyema. If present, both conditions would likely have required intervention. As the underlying pathology was cholecystitis with ischaemia, a percutaneous cholecystostomy may have been a satisfactory option. However this option may not have worked as well in an

empyema of the gall bladder. While the decision to operate was most likely correct, the diagnosis of acute acalculous cholecystitis meant that this decision should perhaps have been made earlier.

Inability to control the patient's bleeding during the laparoscopic cholecystectomy resulted in a conversion to open surgery. At the time the operation was performed the patient's INR was still high (1.7) despite preoperative administration of vitamin K. Full reversal of the anticoagulation could easily have been achieved in the 4 days between admission and surgery. There was no record of a haematologist being consulted or discussion of the possible use of Prothrombinex®-VF to achieve the reversal. FFP was given intraoperatively.

Editor's note: most studies and authorities recommend the use of Prothrombinex®-VF in urgent situations and state that reversal of warfarin effects may occur in as little as 15 minutes.

## CASE STUDY 15: PERIOPERATIVE ANTICOAGULATION - A DOUBLE-EDGED SWORD

### CASE SUMMARY

This patient in their 80s was transferred from another hospital with a short history of nausea, vomiting, mild RIF and abdominal tenderness and distension. The patient had undergone a previous open appendectomy at the age of 13. The presumed diagnosis was adhesive small bowel obstruction.

The patient was otherwise well, and lived independently with minor help for some activities of daily living. She had a significant past medical history including an acute myocardial infarction in 2011 and hypertension. This patient had an advance directive in place in the event of sudden deterioration.

The patient was managed conservatively for 48 hours following admission, although there were ongoing high levels of nasogastric output, and failed passage of oral contrast. The patient had continuing abdominal tenderness so an informed decision was made to proceed to surgery.

During her admission she developed some chest pain and tachycardia which was appropriately investigated. ECG's revealed AF which resolved spontaneously, and serial troponin rose from 0.29 to 1.4. Physicians reviewing the patient suggested that, given her history of acute myocardial infarction, this may represent acute coronary syndrome. Anticoagulation as well as antiplatelet therapy were suggested. Aspirin was given preoperatively and there was a recommendation that the patient receive full anticoagulation following the procedure.

The intraoperative findings consisted of a food-bolus obstruction in the mid-jejunum. An enterotomy was made to extract hard, pebble-like faeces. Minimal adhesiolysis was performed without resection. The patient was admitted to the ICU postoperatively due to concerns about her cardiac status but she was transferred to the CCU shortly after.

The patient commenced a heparin infusion 6 hours postoperatively with an initial bolus. The patient's first activated partial thromboplastin time was >200 at 6 hours, with subsequent dose reduction to within therapeutic range. The heparin infusion was continued throughout her admission.

On postoperative day one the patient had ongoing nausea and vomiting with abdominal distension, and was thought to have an ileus. The patient's haemoglobin was 128 on postoperative day one, dropping to 89 on postoperative day two. On the evening of postoperative day two the patient had a dropping urine output as well as an increasing heart rate, although her BP was stable at 90-100 systolic. The patient was thought to be dry and was given a fluid bolus.

During the morning ward round on postoperative day three the patient was found to be unresponsive. A MET call was made and urgent haemoglobin returned at 47. Discussions were held with the family outlining recent events and the patient's wish to not receive heroic invasive intervention in the case of deterioration. A decision was made to palliate the patient.

The patient passed away shortly after. Her death was most likely secondary to hypovolemia resulting from an intra-abdominal bleed.

### CLINICAL LESSONS

This case highlights the importance of careful and measured approach to commencing anticoagulation

following major abdominal surgery. It is likely that the mortality of this patient was contributed partially by her heparin infusion which was initially supratherapeutic. Anecdotally, it is not uncommon for heparin infusions to be supratherapeutic following initial bolus dosing. It would be beneficial to have different protocols for commencing heparin infusions following surgery for patients who do not present initially with a thrombotic complication, and those patients who do.

Commencing an infusion at the appropriate Unit/kilogram rate without bolus dosing may help prevent initial peaks in postoperative patients. While it was not possible to determine whether operative technique was responsible for the patient's postoperative bleed, there was nothing in the intraoperative findings documentation or procedural notes that raised concern. In retrospect, consideration should have been given earlier, on the evening prior to her death, as to whether postoperative bleeding was the cause of the reducing urine output and increasing heart rate. If the bleed had been recognised at this time the heparin could have been stopped and its effects reversed with protamine. This may potentially have improved the outcome for this patient.

There was good documentation regarding this patient from all medical teams involved during her inpatient stay. An Acute Resuscitation Plan had been completed at the time the patient first arrived at the treating hospital,

helping prevent confusion and ensuring the treatment provided complied with her own personal preferences.

## CASE STUDY 16: ABOVE KNEE AMPUTATION – BEWARE

### CASE SUMMARY

A middle-aged person was admitted to hospital via outpatients with a TKR that had become infected. An attempt to treat the infection with a two stage revision was unsuccessful and it was suggested that an above-knee amputation might be appropriate.

The patient had a past history of recurrent PE and was on subcutaneous heparin. Multiple comorbidities were present including hypertension, asthma, peripheral vascular disease, chronic pain syndrome and anaemia.

The patient was appropriately reviewed by the orthopaedic and infectious diseases teams, and subsequently underwent above-knee amputation.

The amputation was performed without complication and the patient showed reasonable progress during the early postoperative period. Fever developed some days later and it was suspected that the patient had an infection in the wound. A series of wound washouts were performed and an ultrasound suggested the presence of a pseudoaneurysm.

The patient subsequently showed slow but reasonable progress, and with the assistance of vacuum-assisted closure dressings, and a complex antibiotic program, the

patient mobilised quite well.

The patient experienced a fall during the mobilising process and bled profusely from the end of the stump. The patient was immediately taken to the ICU where they had a cardiac arrest. The surgeons felt that it was unlikely that they would be able to control the bleeding; and the patient was not able to be resuscitated.

### CLINICAL LESSONS

This patient had multiple comorbidities. There then had been a complication of the surgical intervention and with a background of PE and treatment for DVT, complications developed that led to infection in the amputation stump.

Despite this patient receiving care in the ICU the progressive bleeding continued, resulting in cardiac arrest. The key lesson arising from this case is that above-knee amputation is not necessarily a benign condition, and can result in progressive sepsis with catastrophic haemorrhage.

## CASE STUDY 17: FATAL PULMONARY EMBOLUS AFTER DELAYED DVT PROPHYLAXIS

### CASE SUMMARY

A patient in their mid-70s was admitted for a knee replacement. The operation proceeded uneventfully and the patient's initial postoperative recovery was unremarkable. In the middle of the day on postoperative day six the patient was assisted to the toilet. A short while later the alarm was sounded and the patient was found collapsed.

Resuscitation was unsuccessful. A postmortem was not undertaken.

### CLINICAL LESSONS

This case illustrates the points outlined below.

1. The sudden collapse of a patient while on the toilet is a classical presentation of PE. While a PE was considered the likely diagnosis by the medical officer attending the arrest call, it does not appear to have been considered as a possible diagnosis by the surgeon.
2. The surgeon indicated that subcutaneous heparin was used as DVT prophylaxis. Based on the medication chart the first dose of subcutaneous heparin was given some 30 hours after the commencement of the surgery. The nurse progress chart suggests that a foot pump was used on the operation day, but neither a pump nor antiembolic stockings were used thereafter.
3. Knee surgery is a high risk procedure for DVT and PE. Prophylactic subcutaneous heparin was presumably the surgeon's intended antithrombotic management strategy, and should have been commenced as soon as possible in the postoperative phase.
4. A fatal postoperative PE has to be considered an adverse event regardless of its cause or preventability.
5. While the clinical scenario strongly suggests that this patient died as a result of a PE it is regrettable that

a postmortem was not performed to definitively determine the cause of death; however, the clinical scenario strongly suggests PE. Although this is an orthopaedic case study, the lessons apply to all surgical specialities.

6. The treating surgeon is ultimately responsible for ensuring that the patient receives adequate DVT prophylaxis. The provision of adequate DVT prophylaxis is, however, a shared problem that requires attention from all medical and nursing staff. Prophylactic measures such as compression stockings and subcutaneous heparin can be prescribed, but must be applied to be effective. It is not uncommon to find patients not wearing their compression stockings. The surgeon in charge needs to be mindful of the situation and encourage junior medical staff and nursing staff to place a high priority on DVT prevention.

## CASE STUDY 18: THE NEW ANTICOAGULANTS...TAKE NOTE!

### CASE SUMMARY

An elderly patient was admitted via the ED with a diagnosis of small bowel obstruction. A CT scan confirmed the diagnosis and a possible transition point. The comorbidities included an anterior resection for colon cancer, diabetes, and AF for which Pradaxa had been prescribed.

The patient was initially managed conservatively. Over the ensuing days the patient experienced continuing

abdominal pain with nausea and vomiting requiring analgesics and antiemetics. Their abdomen was noted to be distended while vital signs showed temperature spikes, tachypnoea and tachycardia on occasions, a white cell count of  $32 \times 10^9/L$  (reference range  $3.7 - 9.5 \times 10^9/L$ ) and an elevated C-reactive protein. No serial imaging studies were done and it is unclear whether there was regular consultant input. The anticoagulant was not ceased.

The patient became acutely unwell on day 10 at which time a laparotomy was undertaken. A small bowel resection was required but it was complicated by sepsis, as well as uncontrollable bleeding in both the intraoperative and postoperative periods. The patient never recovered and died the following day.

### CLINICAL LESSONS

There have been some concerns regarding the ability to monitor the anti-coagulant effects and the ease of reversal of the effects of the drugs. This is particularly important for the newer types of anticoagulant which have the problem of monitoring and the inability to return levels to normal.

The decision to operate on a patient with small bowel obstruction is often a difficult one to make. In this patient, however, there was clear evidence of failure to progress with conservative management. An earlier operation would likely have been prudent.



## SHORTENED FORMS

---

AF	atrial fibrillation
ANZASM	Australian and New Zealand Audit of Surgical Mortality
ASA	American Society of Anesthesiology
BP	blood pressure
CPR	cardiopulmonary resuscitation
CT	computed tomography
DVT	deep vein thrombosis
ED	emergency department
FFP	fresh frozen plasma
Fr	French size
HDU	high dependency unit
ICU	intensive care unit
INR	international normalised ratio
MET	medical emergency team
PE	pulmonary embolism
RACS	Royal Australasian College of Surgeons
SAAPM	South Australian Audit of Perioperative Mortality
SMA	superior mesenteric artery
SMV	superior mesenteric vein
STEMI	ST segment elevation myocardial infarction
TKR	total knee replacement

## CONTACT DETAILS

---

Royal Australasian College of Surgeons  
Australian and New Zealand Audit of Surgical Mortality  
199 Ward Street  
North Adelaide SA 5006  
Australia

Telephone: +61 8 8219 0900

Facsimile: +61 8 8219 0999

Email: [gordon.guy@surgeons.org](mailto:gordon.guy@surgeons.org)

Website: [www.surgeons.org/for-health-professionals/audits-and-surgical-research/anzasm.aspx](http://www.surgeons.org/for-health-professionals/audits-and-surgical-research/anzasm.aspx)

The information contained in this case note review booklet has been prepared on behalf of the Royal Australasian College of Surgeons, Australian Audit of Surgical Mortality Steering Committee. The Australian and New Zealand Audit of Surgical Mortality, including the Western Australian, Tasmanian, South Australian, Australian Capital Territory, Northern Territory, New South Wales, Victorian and Queensland Audits of Surgical Mortality, has protection under the Commonwealth Qualified Privilege Scheme under Part VC of the *Health Insurance Act 1973* (gazetted 23 August 2011).

## NOTES

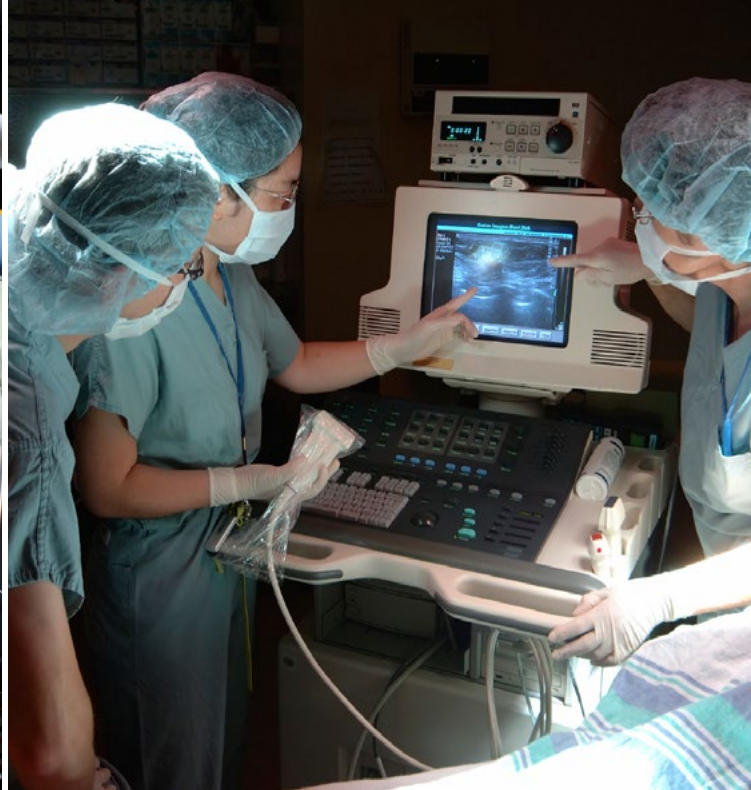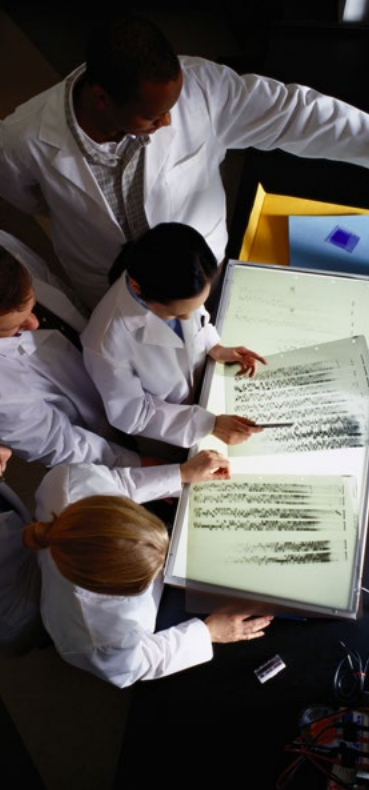---

.....  
.....  
.....  
.....  
.....  
.....  
.....  
.....  
.....  
.....  
.....  
.....  
.....  
.....  
.....  
.....  
.....  
.....  
.....  
.....  
.....  
.....  
.....  
.....  
.....  
.....  
.....  
.....  
.....  
.....  
.....  
.....  
.....  
.....  
.....  
.....  
.....  
.....  
.....  
.....  
.....  
.....  
.....  
.....  
.....  
.....  
.....  
.....  
.....  
.....  
.....  
.....

## NOTES

---

.....  
.....  
.....  
.....  
.....  
.....  
.....  
.....  
.....  
.....  
.....  
.....  
.....  
.....  
.....  
.....  
.....  
.....  
.....  
.....  
.....  
.....  
.....  
.....  
.....  
.....  
.....  
.....  
.....  
.....  
.....  
.....  
.....  
.....  
.....  
.....  
.....  
.....  
.....  
.....  
.....  
.....  
.....  
.....  
.....  
.....  
.....  
.....  
.....  
.....  
.....  
.....  
.....  
.....  
.....  
.....



Royal Australasian College of Surgeons  
Australian and New Zealand Audit of Surgical Mortality  
199 Ward Street, North Adelaide SA 5006, Australia

Telephone: +61 8 8219 0900

Facsimile: +61 8 8219 0999

Email: [gordon.guy@surgeons.org](mailto:gordon.guy@surgeons.org)



ROYAL AUSTRALASIAN  
COLLEGE OF SURGEONS

[www.surgeons.org/for-health-professionals/audits-and-surgical-research/anzasm.aspx](http://www.surgeons.org/for-health-professionals/audits-and-surgical-research/anzasm.aspx)

