



Victorian Audit of Surgical Mortality

CASE NOTE REVIEW BOOKLET

Fifth Edition | November 2013



ROYAL AUSTRALASIAN COLLEGE OF SURGEONS



CONTENTS

INTRODUCTION	3
SUMMARY OF REVIEWERS COMMENTS ON INDIVIDUAL CASES	4
EMERGING ISSUES	6
CARDIOTHORACIC SURGERY	7
Case 1: Benefit versus risk in cardiac surgery	7
Case 2: Right ventricular artery injury during re-sternotomy	8
GENERAL SURGERY - COLORECTAL	11
Case 3: Colonic cancer diagnosis missed	11
GENERAL SURGERY	13
Case 4: When in doubt, seek second opinion	13
Case 5: Caution with colonic resection for diverticular disease	16
Case 6: Cholangitis needs complete drainage	18
NEUROSURGERY	20
Case 7: Late referral is often fatal in subdural haematoma	20
Case 8: Postoperative patients need a care plan and timely investigation	22
ORTHOPAEDIC SURGERY	24
Case 9: Allow time for preoperative assessment	24
Case 10: Delay in diagnosis of fractured neck of femur can be fatal	26
Case 11: Patient care postoperatively	29
GYNAECOLOGICAL/VASCULAR SURGERY	31
Case 12: Inability to contact on-call surgeon	31
VASCULAR SURGERY	37
Case 13: Beware of ceasing anticoagulation in high embolic risk patient	37
Case 14: Second look laparotomy after IMA bypass may be advisable	39
LIST OF SHORTENED FORMS	41
NOTES	42



INTRODUCTION

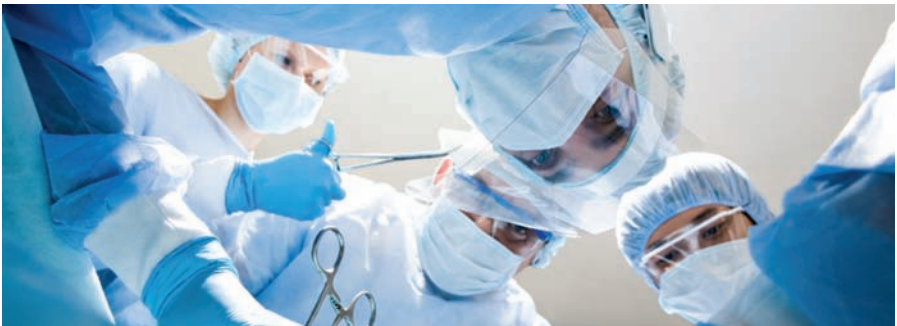The audits of surgical mortality review deaths that occur whilst under the care of a surgeon in the public and private hospital sectors. As this peer review process is intended as an educational exercise, we have selected a number of cases that bring out specific clinical issues. The cases do not necessarily relate to the period since the last booklet. They do, however, serve as topical and timely lessons for all surgeons and clinical team members.

All cases selected have gone through a second-line assessment (case note review) by a Fellow from either the Royal Australasian College of Surgeons or the Royal Australian and New Zealand College of Obstetricians and Gynaecologists. The cases document critical incidents, often involving system issues rather than issues that are the responsibility of the treating surgeon alone. The assessments have been edited to ensure that the patient, hospital, treating surgeon and assessor remain anonymous.

Qualified Privilege (QP) prevents us from sending assessment feedback to anybody other than the treating surgeon. This means that hospital management only receive indirect feedback on cases of patients who died in their hospital. The surgeon can, of course, share the outcome of their assessment with relevant staff. Where there are obvious system issues, it is important that hospitals are aware and react to address these issues as appropriate. It is also important that the audit attempts to address emerging adverse trends.

We feel that, as there are important lessons in this publication, it should be made available to all those responsible for delivering the care that resulted in the outcomes presented and recommend that it be used as a teaching aid. Additional copies of this publication can be provided as necessary.

Audit staff would like to take this opportunity to thank all surgeons and hospitals participating in this educational activity. We hope you find this publication of value.





SUMMARY OF REVIEWERS COMMENTS ON INDIVIDUAL CASES

Case 1

Perform the minimum procedure necessary to achieve the best chance of success for high-risk patients.

Case 2

Perform all possible investigations to predict a life-threatening intraoperative complication.

Case 3

Failure to diagnose a malignant obstruction in an obvious clinical setting led to significant treatment delay.

Case 4

In a very high-risk patient, obtain multiple opinions and don't allow pressure by family members to sway judgement.

Case 5

Colonic anastomoses after resection for diverticular disease has a high disruption rate; the surgeon should have a low threshold for diverting stoma and be alert to any clinical deterioration.

Case 6

Endoscopic retrograde cholangiopancreatography for multiple common bile duct calculi is better performed under general anaesthetic. Inadequate drainage proved to be fatal.

Case 7

Delay in referral of a head injury to neurosurgery after admission to Emergency Department has serious consequences.

Case 8

Any postoperative deterioration in a neurosurgical patient should have prompt investigation and notification of the consultant.

Case 9

Elective patients undergoing orthopaedic surgery should have thorough preoperative assessment.



Case 10

Delay in diagnosis and treatment of fractured neck of femur by the Emergency Department, because of clopidogrel, led to the demise of this patient.

Case 11

Inadequate postoperative management because of a lack in allocated medical or High Dependency Unit support made fluid management of this complicated patient difficult.

Case 12

Delay in contacting a vascular surgeon resulted in the death of this patient. Iatrogenic vascular trauma during laparoscopy is preventable. General surgeons should be able to control major vascular injury until help arrives.

Case 13

The difficulties of managing anticoagulation in a high-embolic-risk patient were made more complex with repeated operation cancellations. This resulted in a repeat embolic event and, in the setting of comorbidities, resulted in prolonged hospitalisation and death from respiratory sepsis.

Case 14

Always re-implant the inferior mesenteric artery if large and not back-bleeding during aortic replacement. Have a low threshold for performing a second-look laparotomy.



EMERGING ISSUES

Leadership in patient care

- In complex cases there must be clear demonstrable leadership in patient management. The treatment plan for each patient should be understood by all involved with the patient's care.

Documentation of clinical events and plans

- The case record is an essential tool for identifying clinical trends and management plans. As such, the case record must contain clear, accurate documentation of events and plans.

Failure to act on evidence of clinical deterioration

- This is an issue that is recognised throughout Australia and internationally.
- When clinical deterioration occurs in a patient and there is no clear cause, remember the cause may be related to something outside your specialty knowledge base.
- Clinical findings must be considered along with the results from any investigations.
- Clinical deterioration must be acted upon not just recorded.

Preoperative management

Appropriate preoperative preparation and management may decrease operative complications and promote successful recovery. Preparation and management should include:

- Evaluation of both physical and psychological preparation.
- Complete medical history and physical examination procedures.
- Consent for the surgery and discussion of potential outcomes.
- Appropriate documentation and communication of findings with clinical and surgical teams.

Postoperative management

- The patient should be discharged to the ward with comprehensive orders.
- Preventative measures are to be implemented for reducing complications.
- Instructions must be given about further management if discharged from a clinical or surgical team.
- The potential outcomes from the probable clinical diagnosis must be considered when developing a treatment plan.



CARDIOTHORACIC SURGERY

Case 1: Benefit versus risk in cardiac surgery

Clinical details

The patient was aged in their late-70's and died three days subsequent to elective mitral valve replacement, tricuspid valve repair and Cox-Maze IV procedure. The patient's comorbidities included chronic renal impairment, chronic Atrial Fibrillation (AF) and protein C deficiency. The patient had undergone Transurethral Resection of the Prostate (TURP).

The patient underwent an uneventful operation, albeit with prolonged cross-clamp and bypass times, as would be expected for a double valve and AF ablation procedure. There was postoperative bleeding in the Intensive Care Unit (ICU), with haemodynamic instability, and the chest was re-opened emergently. This was followed by a return to theatre where a bleeding Right Internal Mammary Artery (RIMA) was found, presumably related to the sternal wiring process. The patient was returned to ICU but failed to thrive, developing vasodilatory shock and multi-organ failure that resulted in death on postoperative day three.

Comments

The addition of a Cox-Maze procedure to double valve surgery in this patient was an interesting decision. It would have added time to the cross-clamp and bypass runs therefore increasing operative risk without a clear benefit in someone with

long-standing AF and with a predisposition to thrombosis (protein C deficiency). This patient would likely have needed some form of anticoagulation postoperatively in any case. From the operative report, there was substantial coagulopathic bleeding in the first operation, likely due to the long bypass run, culminating with postoperative bleeding requiring re-sternotomy which was a significant stress to the patient and would have contributed to the patient's overall demise a few days later. The assessor would have preferred to omit the AF ablation procedure in this case.

From the notes, it seems that the overall postoperative management of this patient was appropriate; there was no major delay in returning to theatre (although the exact timing is unclear from the notes provided) and the ICU care was satisfactory in the time the patient was under their care. The exact role the protein C deficiency played in this patient's overall operative course is unclear. However, it appears the haematology department signed off on having surgery and all usual measures were taken regarding clotting and bleeding management in the perioperative period.

The addition of a Cox-Maze IV procedure to this elderly patient who was already undergoing double valve surgery may have placed added risk to the postoperative course for little achievable benefit.



CARDIOTHORACIC SURGERY

Case 2: Right ventricular artery injury during re-sternotomy

Clinical details

This case involves the death of an elderly patient who underwent redo Coronary Artery Bypass Surgery. The patient had undergone a Coronary Artery Bypass Graft (CABG) in 1995. The initial operation was complicated by graft failure which required a reoperation and placing of another vein graft. The patient previously had stable anginal symptoms but re-presented with prolonged chest pain and a small troponin rise. A coronary angiogram was performed and demonstrated significant triple vessel coronary artery disease and graft disease.

During the re-sternotomy, the Right Ventricle (RV) was injured. Peripheral cannulation, the sternotomy and division of the previous pericardial adhesions was undertaken. The assistance of the head of the cardiothoracic unit was employed at this time and the RV was repaired. The procedure was completed with the performance of three vein grafts. The patient was weaned from cardiopulmonary bypass utilising inotropic support. At the time of chest closure, the patient went into ventricular fibrillation and required ventricular decompression and cardioversion. The RV was perforated at this time. The patient had to be re-cannulated and cardiopulmonary bypass reinstated. The RV was then repaired again with the assistance of the head of the unit.

Haemostasis was again secured, with the need for significant clotting factors and the use of factor VII. The patient was returned to the Intensive Care Unit (ICU) with a significant inotrope requirement. The condition of the patient slowly deteriorated. An echocardiogram demonstrated significant RV dysfunction. The decision was made to take the patient to the operating theatre to exclude tamponade; however, there was a rapid deterioration in the condition and an emergency re-sternotomy was required. There was no evidence of tamponade; however, there was evidence of severe RV dysfunction. The surgical team decided that the situation was irretrievable and the patient died.

Comments

The patient died as a result of RV failure. This resulted from two episodes of RV injury: one was following the re-sternotomy and the second following the ventricular decompression and cardioversion that followed the first bypass run. RV injury is a known and serious complication of redo sternotomy. The identification of RV attachment to the sternum preoperatively indicates a high risk of injury at the time of re-sternotomy. If this is identified, peripheral cannulation and institution of cardiopulmonary bypass decompresses the RV to allow a safer re-entry. A lateral chest x-ray is the traditional method of ascertaining the relation of the RV to the sternum; however, this is unreliable.



A Computed Tomography (CT) scan is a more sensitive and specific method. From review of the notes, it is not clear whether a lateral chest x-ray was undertaken.

A chest x-ray was performed in the Emergency Department (ED); however, it is not clear whether this included a lateral examination. There is no report of a CT scan. In this case, the old operation notes were not available and, therefore, it was unknown whether the pericardium was closed or not. In addition, the initial operation was complicated and required a re-operation with placement of a further graft to the Left Anterior Descending artery (LAD). This would suggest an increased level of suspicion that the pericardium was not closed and that the RV may be proximate to the sternum.

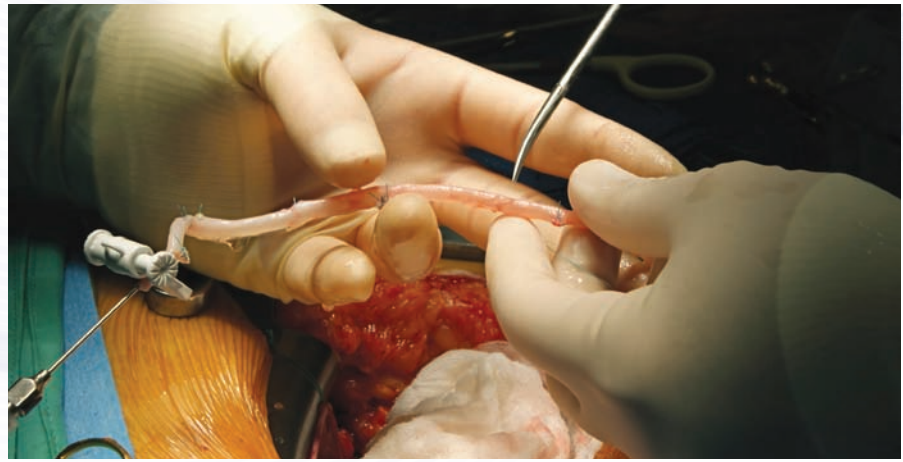The technique of sharp dissection behind the sternum with retraction and direct vision is a sound one. The decision to then proceed to peripheral cannulation and gain assistance from an experienced second surgeon is also to be commended. The episode of ventricular fibrillation at the time of chest closure is likely to be multifactorial. After a prolonged operation, it is possible that there is significant myocardial oedema and, on occasion, it is not possible to close the sternum without compression and a resultant hypotension. It is also possible that with the use of multiple clotting factors there may have been a reaction to the product transfusions or, potentially, the

graft, or small vessel thrombosis may have occurred. The patient's age and preoperative steroid use would have likely meant that the tissues were weak and, in the attempt to decompress the Left Ventricle (LV), the RV was perforated. This necessitated a further cardiopulmonary bypass run which would have exacerbated the bleeding issues and the RV oedema. The use of factor VII after coronary artery bypass surgery is concerning to some surgeons who worry about the increased risk of graft thrombosis, particularly at the anastomotic sites. The patient follow-up in the ICU seems to be exemplary. The surgeon's decision to re-explore the patient to exclude the possibility of tamponade is also commended. At this point it was clear that the RV dysfunction was the underlying problem and there was no solution to this.

In summary, the patient died undergoing re-operative coronary artery bypass surgery due to two episodes of RV injury. The first RV injury occurred during the re-sternotomy. The risk of this injury could have been reduced through institution of a peripheral bypass prior to the re-sternotomy if the proximity of the sternum to the RV would have been appreciated preoperatively. A CT scan of the chest is a useful examination in this setting. The surgical team have, however, managed the event of injury to the RV very well. The second injury to the RV occurred as a result of an episode of ventricular fibrillation and

manual decompression of the LV to aid in defibrillation. Possibly, consideration could be given to the direction, force and rate of decompression. With regard to the ICU involvement in the case, it is difficult to tell at what point the Cardiothoracic staff were notified of the patient's deteriorating condition. However, this patient was always in a precarious condition and the level of attention paid by the Cardiothoracic team

should have been high. The escalating inotropes reflect the progressive deterioration in right ventricular function and not any surgically correctable cause. As such, early notification would not have changed the outcome in this situation. Of course, a high level of vigilance from the surgical team and regular communication from the ICU team is to be encouraged.





GENERAL SURGERY - COLORECTAL

Case 3: Colonic cancer diagnosis missed

Clinical details

An elderly patient was admitted with abdominal pain and distension for three days, with faecal vomiting for 24 hours, and the patient's bowel had not been open for five days. The patient also had a virgin abdomen. The patient's abdomen was distended and tympanitic; Naso-Gastric (N/G) drainage was large with more than one litre of faecal fluid draining. There were no relatives who may have helped with management, and the patient's cognitive skills were not good enough to be able to give any sort of history. It also seems that the patient was fairly mobile prior to admission, in that the patient was able to drive a scooter around near their residence.

Following the admission, there were daily ward rounds with the same information being entered each time, as above, but nothing seems to have been done to help the improvement of the patient's status or to arrive at a proper diagnosis. The patient did have a colonoscopy where no pathology was found; the endoscopist should have been able to reach the tumour. The patient had a persistent tachycardia which later became AF when the electrolytes were not corrected (persistent low K+, possibly sequestered in the small bowel). The patient was deemed to be non-cooperative and occasionally confused, but not a lot appears to have been done to improve this state (e.g. fluid

overload, oxygen saturation, nutritional status or electrolyte imbalance).

The patient was discharged four days later, only to be admitted the next day for the same problem. The patient had faecal vomiting for which a N/G tube was inserted; a rectal tube was also inserted. The patient had a distended abdomen. Surgery was undertaken nearly a week after the second admission; the patient had a high anterior resection, during which inotropic support was required. Postoperatively, the patient had a low urinary output for which Frusemide was given in the early hours of the morning.

Comments

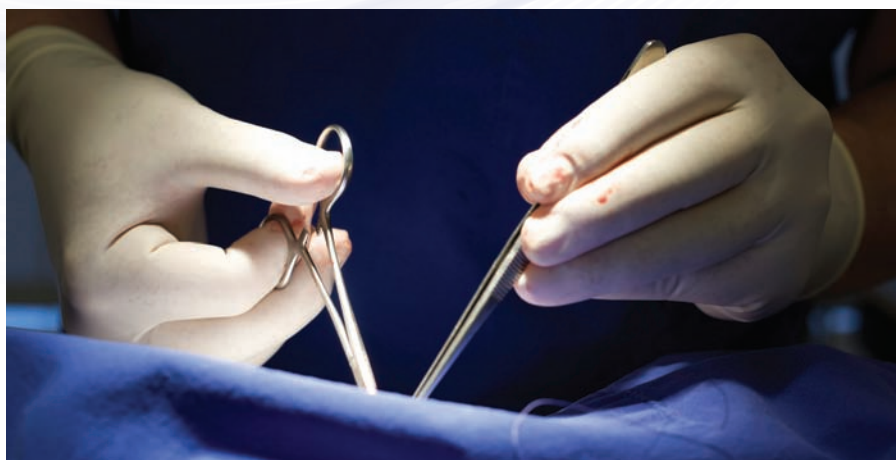
In summary, an elderly patient was admitted to hospital and a colonic cancer was missed until it was too late to guarantee a good outcome. No person associated with this patient's care considered the diagnosis and management was less than satisfactory.

This patient should have had the laparotomy within 48 hours of the first admission. The patient would then have had a greater chance for survival following major surgery. Large Bowel Obstruction (LBO) in an elderly patient with a virgin abdomen signals a colonic malignancy unless definitely ruled out, which was not in this case. The signs were there every time the patient was examined; namely abdominal distension, vomiting (often faecal), very little passage of faecal material via the anus, often no



flatus and often no bowel sounds. The various x-ray examinations that were done seem to support the diagnosis of LBO; the barium enema was strongly suggestive of colon cancer. It appears that no-one stood back and looked at the whole picture to try and work out why this patient was not getting better over a long period of time, considering that the patient was in hospital for a month in the first instance. Another point worth emphasizing is the use of diuretics in postoperative patients; diurnal rhythm dictates that urinary output falls in the early hours of the morning and, often, postoperative patients need fluid to improve the urinary output, not Frusemide. In this scenario, Frusemide only serves to squeeze kidneys, which are at their maximum with a vascular bed that is under-filled, as well as lower the K⁺ further.

In the future, it behoves any person caring for an older patient with the symptoms and signs of bowel obstruction to look carefully and exclude malignancy in the abdomen, especially if there has not been any previous surgery to the abdomen. If the patient is not showing signs of improvement within 24 hours with the usual resuscitation measures, then laparotomy should be strongly considered. I am not sure if there was more than one consultant or registrar caring for this patient, but the fewer persons making decisions, the better the outcome. Electrolyte and nutritional management needs to be looked at from the moment of admission and corrections made as soon as possible with any method available.





GENERAL SURGERY

Case 4: When in doubt, seek second opinion

Clinical details

The case is that of an elderly patient undergoing elective colonic resection for a second colonic cancer. The first resection had been performed 30 years ago and the patient had failed to attend for follow-up colonoscopies. On this occasion, the patient had presented with anaemia, constipation and abdominal pain. In the interval, the patient had also developed cardiac ischaemia leading to Congestive Cardiac Failure (CCF), a left ventricular thrombus and an ejection fraction of 18%. The considerable risks of surgery were discussed with the patient and the patient's family, and the patient was assessed by an anaesthetist and physician preoperatively. An open colectomy was performed. The patient died nine days after surgery, following withdrawal of inotropic support for blood pressure.

Comments

The assessor questioned (as did the treating surgeon) whether this patient was ever going to have a good outcome following surgery. Certainly, the treating surgeon had his doubts and the statement "just because the patient and the patient's family want it" should never influence our surgical judgment. The surgeon may have considered using various predictive scoring systems – such as the Colorectal Physiological and Operative Severity Score for the enumeration of Mortality and

Morbidity (Cr-POSSUM) or the Association Française de Chirurgie (AFC) score – in an attempt to dissuade the patient from surgery, although the evidence is that if the surgeon has a gut feeling that the risks are high, it is generally correct. Some support from the physician and anaesthetist may have helped also. Seeking a second opinion from another surgeon would have also been an option. An advanced care directive for use after surgery may have been useful in this case.

One of the major areas of concern was the use of an epidural in a cardiac-compromised patient and the duration for which it was used. Although there is some evidence that epidurals provide superior pain relief following abdominal surgery and assist with postoperative respiratory problems, they may cloud the true picture of intra-vascular filling volumes and blood pressure such that the postoperative days become a nightmare of overfilling with fluids to chase a low blood pressure followed by wringing the patient out because the patient is too "wet". This case demonstrates that issue precisely. Not only was the patient in a positive fluid balance of twelve litres, the patient was also on a constant noradrenaline infusion from the time of surgery to the day of death. Dobutamine was added to the mix in the final two days of life and Frusemide used as required to improve urine output. In a patient whose ejection fraction is already poor, an alternative form of postoperative analgesic could have been considered,



such as a Transverse Abdominis Plane (TAP) block or a Patient Controlled Analgesia (PCA). The epidural was removed on day three and a PCA was used followed by TAP block insertion on day five, but by this stage, the patient had developed an acute rise in the liver enzymes together with a decreasing urine output. Possibly, the patient was severely underperfused despite the large quantities of intravenous fluids (i.e. patient was third-spacing). There is also some mention in the notes about surgical emphysema (day two postoperatively), although this isn't mentioned in any of the x-ray reports and the possibility of anastomotic leak is never entertained as a cause of the patient's deteriorating condition (an abdominal ultrasound was performed on day five and this did not reveal any major fluid collections).

There were no identifiable adverse events. The first-line assessor calls for comments on the postoperative care, the duration of the epidural and the hypotension. The epidural was only used for three days following the surgery, but it was not the best choice of postoperative analgesia for the reasons outlined above. Given the considerable risk of death in this patient and the irreversible nature of the patient's medical comorbidities, the assessor thinks the postoperative care was an attempt to make the best of a bad situation. The patient's demise was inevitable once the ionotropic support was withdrawn.

It would appear that the surgeon involved in this case was not keen on performing the surgery due to the high risk of postoperative complications and death which was clearly and instinctively recognised from the outset. Perhaps a more frank discussion about this would have been appropriate or, if this had occurred, perhaps a second opinion from another surgical colleague would have convinced the patient and the patient's family of the considerable risk.

Clearer directives about the duration and type of interventions may have been appropriate in order to prevent the prolongation of futile treatment.

The use of epidurals with the concomitant merry-go-round of hypotension and fluid overload, particularly in post-abdominal surgical patients, needs to be seriously examined.

Anaesthetic Review

1. The decision to operate and perioperative planning

The best indicator of perioperative risk is the opinion of the treating surgeon. On occasion, a surgeon may feel a patient is at such high risk for complications due to comorbidities that further consultation around the wisdom of proceeding with elective surgery should be sought. In these circumstances, perhaps there is value in considering a preoperative case conference, that is, a "round table" discussion by key members of the perioperative care team



including the surgeon, the anaesthetist, an intensivist, a physician, and/or other clinicians.

Models for similar approaches exist in some specialty areas, such as cardiac surgery. Perhaps it is time to consider the value of these approaches for other complex, high-risk surgical cases. The assessor observes that when, for example, anaesthetists are consulted on an individual clinician basis, it is often perceived that the question they are being asked is “can they provide the clinical service” rather than “should it be provided”. With a “round table” approach, the broader question of overall risk versus benefit can be more easily addressed.

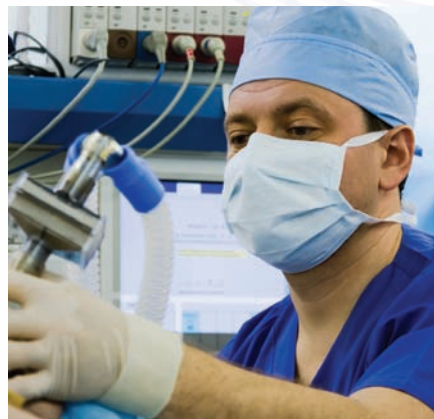It would be of value for such preoperative discussions to also consider limitations of treatment or advanced care directives. Not only would this help ensure that postoperative care decisions are informed by the patient’s wishes, but it may also make it easier to revisit such discussions in the postoperative period if needed.

2. The choice of postoperative analgesia and its management

It is difficult to pass comment on the cause of hypotension in this case from the detail provided. In general, in a patient with cardiac comorbidities, the need for careful monitoring and management of fluid balance is always going to be of prime concern. The addition of a sympathetic block from an epidural can make this

situation even more challenging. Epidural analgesia is an established analgesic technique for abdominal surgery in high-risk patients. If used in a patient with cardiac comorbidities, the continuous measurement of cardiac filling pressures in a critical care setting (for as long as the block is haemodynamically significant) can satisfactorily guide fluid management.

Regarding duration of use of the epidural catheter, three days is not unusual. It is unclear from the information provided whether the epidural was removed at three days in this case due to hypotension or for another reason. In general terms, there is always a payoff between wanting to keep the epidural for as long as possible to provide adequate analgesia and taking it out before the catheter becomes colonised, with the attendant risk of epidural space infection.





GENERAL SURGERY

Case 5: Caution with colonic resection for diverticular disease

Clinical details

An elderly patient with unknown comorbidities was admitted to a peripheral hospital for surgery for diverticular disease. The indication for surgery is not well described as the initial surgeon's notes have not been made available. However, the ambulance report suggests surgery was for "pain/bleeding issues". A laparoscopic-assisted high anterior resection was performed. The anastomosis was end-to-end stapled with negative leak test. There is no description of the state of resected bowel or presence of adhesions. There is no description of any diverting stoma being performed and no description of any operative difficulties.

There are no notes on the first two days of the postoperative period, but on day three, the patient is described as tachypnoeic, septic and oliguric with suspected abdominal sepsis prompting transfer to another hospital with critical care facilities. A Computed Tomography (CT) scan suggested anastomotic leak. After a brief period of stabilisation in hospital two, the patient was taken to the Operating Room (OR).

The second operation confirmed anastomotic leak with faecal peritonitis. The anastomosis was taken down, the rectal stump oversewn and the proximal end brought out as a stoma. Following this,

there was a prolonged turbulent course in the Intensive Care Unit (ICU). Upon withdrawal of sedation, the patient was noted to have a left hemiparesis. A CT scan confirmed a right hemisphere ischaemic stroke. Over the next few weeks, the sepsis seemed to come under control and the patient was discharged to the ward.

At three weeks post operation, the patient went into respiratory failure. A decision not to readmit to ICU was made following discussion with the family. Death occurred shortly after. It is of note that, at this time, the patient was receiving enteral nutrition via tube.

The Coroner's postmortem indicates death due to abdominal sepsis, with multiple sites of sepsis leading to multisystem failure. There was no evidence of pulmonary embolus or aspiration.

Comments

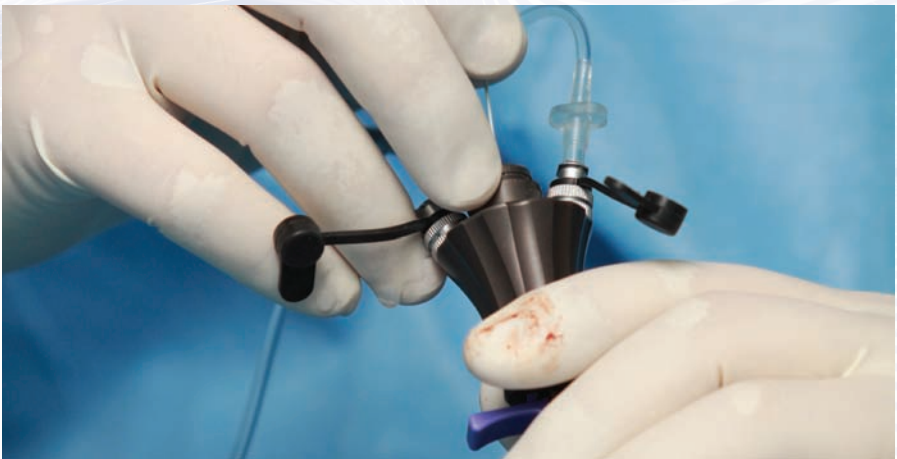Death occurred due to anastomotic leak following high anterior resection. The notes from the original procedure are scant and do not indicate the state of the abdomen and colonic disease. Also the indications for surgery are not spelt out.

The leak seems to have been acted upon promptly and the subsequent treatment completely appropriate. The decision to withdraw treatment at the end was reasonable given the morbidities that had developed.



The leak rates following surgery for diverticular disease are higher than other elective indications. The symptomatic relief gained from surgery depends on the indication. Pain is not well palliated by surgery. If bleeding were the indication, there should be a record of investigations seeking the source of bleeding, which is not the case.

Colonic resection for diverticular disease should be approached with caution. There should be a low threshold for a diverting stoma to protect the anastomosis.





GENERAL SURGERY

Case 6: Cholangitis needs complete drainage

Clinical details

An elderly patient had previously been admitted, two months prior to the admission in question, with gallstone pancreatitis and cholangitis. An Endoscopic Retrograde Cholangiopancreatography (ERCP) was performed during that initial admission with incomplete clearance of the common bile duct and insertion of a biliary stent. The patient was discharged to a rehabilitation hospital with a planned readmission for repeat ERCP and clearance of the patient's biliary stones. There was a past history of hypertension, diabetes and recurrent urinary infections for which the patient was taking norfloxacin.

At ERCP on first day of this admission, the patient's previously inserted stents were removed and five large stones extracted. There appeared to be one remaining stone in the proximal end of the common bile duct, but this was not removed as the patient desaturated and required intubation at that stage. The patient was transferred to the Intensive Care Unit (ICU) following ERCP but was extubated after three hours and returned to a ward bed. The patient was seen that night by a resident who addressed concerns regarding urine output. It was decided to continue the patient's intravenous fluids overnight with a bolus of fluid given.

The patient was seen on a ward round the following morning and, being well,

an order was given to have the patient's intravenous cannula and catheter removed. Arrangements were being made to transfer the patient back to the rehabilitation hospital.

A few hours later, the patient was found to be febrile and non-responsive, with low oxygen saturations. Blood cultures from the previous day were found to be Vancomycin-Resistant Enterococci (VRE) positive and the patient was commenced on intravenous fluids and antibiotics. A discussion was held with the infectious diseases team and the patient's antibiotic treatment was altered. A subsequent Medical Emergency Team (MET) call was made for continuing sepsis associated with hypotension and it was decided to send the patient back to ICU. A Computed Tomography (CT) scan was ordered which showed evidence of common bile duct dilation and a large retained stone in the common bile duct. There were no signs of pancreatitis or perforation.

The patient remained septic and it was felt that the cause of the sepsis was a retained stone in the common bile duct, with cholangitis. A further ERCP was performed on day three and demonstrated a dilated common bile duct with a large calculus. The stone was not removed as there were anaesthetic concerns with hypotension, but two plastic stents were inserted with a request that they be removed in approximately six weeks. The patient remained in a poor condition following the



ERCP and required continuing ventilation and inotrope support. Despite this, the patient's urine output was poor and failed to respond to Frusemide infusions.

The patient's condition did stabilise and the patient was able to be extubated the following morning with reasonable saturation post-extubation. The patient required small doses of inotrope to maintain the patient's blood pressure but the urine output was minimal. The patient's liver function tests were improving and, despite the patient's renal failure, the patient was discharged to the ward on day five.

Whilst in the ward, the patient's condition did not improve and the renal failure worsened. After a family discussion, it was decided that the patient would receive haemofiltration but that the patient would need to go back to ICU for this to be given as inotrope support would be required. At this stage, a chest x-ray suggested acute pulmonary oedema.

The patient's condition continued to deteriorate and a decision was made to treat the patient palliatively. The patient died shortly afterwards.

Comments

Acute cholangitis due to gallstones is a very significant and life threatening condition, particularly in elderly patients with medical comorbidities. The second-line assessor was in agreement with the first-line assessor's comments that the patient should have been given a full anaesthetic

for the ERCP rather than sedation. It is likely that the patient would have tolerated the procedure much better and may not have suffered an episode of collapse. The second-line assessor was unaware from the notes whether the patient was given any prophylactic antibiotics with the procedure, but the patient certainly should have been given antibiotics for the first procedure. The patient was placed on antibiotics when a MET call was necessary following the first procedure and the patient's blood cultures were found to be positive.

At the second ERCP, the patient's stents were removed prior to incomplete clearance of the common bile duct. In the presence of a retained large stone, the assessor believes the patient's stent should have been reinsterted to prevent further episodes of cholangitis and septicemia. Following the second admission to ICU with septicemia, treatment seemed to be adequate, but the patient was discharged from ICU with worsening renal failure. After 48 hours, the patient was transferred back to ICU as it was decided that the patient would receive haemofiltration and this would require a stay in ICU with appropriate nephrology treatment for the patient's renal failure. The patient's fluid management during their stay in hospital seemed less than ideal, and the obvious cause of the patient's renal failure was due to pre-existing renal problems as well as sepsis and hypovolaemia.



NEUROSURGERY

Case 7: Late referral is often fatal in subdural haematoma

Clinical details

This patient, aged in their mid-40s, had presented to the audited hospital with a Grade V acute subarachnoid haemorrhage from a large basilar tip aneurysm rupture. The aneurysm was coiled endovascularly and the patient required a prolonged stay in Intensive Care Unit (ICU). The patient eventually recovered enough to speak in full sentences, even though confused, and was able to spontaneously move the left arm and left leg. The patient had a residual right hemiparesis.

The patient was discharged to another hospital for rehabilitation. The medical course of events prior to discharge included a Non-ST Elevation Myocardial Infarction (NSTEMI) the day following admission with pulmonary oedema and a right cephalic vein thrombosis secondary to a right subclavian central venous catheter. The patient had a percutaneous tracheostomy inserted 10 days later and then had a percutaneous gastrostomy inserted.

The patient apparently had multiple falls while in the rehabilitation facility, associated with increasing headache and confusion. They had been on clexane, 60 mg twice daily.

The patient was noted to be unconscious and was transferred back to the parent hospital, arriving in the Emergency Department (ED) at 1050. The Glasgow

Coma Score (GCS) was 4/15. It seems from the notes that the patient was observed in the ED until 1530 when they were finally transferred to the Radiology Unit for a Computed Tomography (CT) scan of the brain.

The patient was reviewed by the neurosurgery team at 1600. A CT scan of the head revealed a large right acute subdural haematoma. The patient was taken immediately to the Operating Room (OR) for craniectomy and evacuation of the right subdural haematoma. There is no indication that an intracranial pressure monitor or an External Ventricular Drain (EVD) was inserted during this operation. The brain was very swollen according to the operative notes, and the surgeon was unable to close the dura.

The patient was managed in the ICU after surgery. A postoperative scan of the head performed on the following day showed good evacuation of the acute subdural haematoma but very swollen and oedematous brain, extending markedly through the craniectomy site.

Brain stem reflex testing for brain death was performed two days after the CT scan confirmed brain death. Life support was ceased and the case was referred to the Coroner's Office.

Comments

The surgical team reporting on this case indicated that there had been a prior admission to the ED. These notes were not available. According to the reporting



surgical team, the CT scan of the head was apparently normal, but no consultation to the neurosurgery team was made. The treating surgical team felt that, due to the patient being on anticoagulation, a neurosurgical referral should have been made. In addition, they also felt that strict and close neurological observations and a repeat CT scan of the brain were recommended, which may have picked up the acute subdural haematoma at an earlier stage.

What is most concerning is that the patient was admitted to the ED at 1050, in a coma, with a Glasgow Coma Score (GCS) of 4/15. For reasons that are unknown, the patient was not referred to neurosurgery and no CT scan of the head was performed until 1530. The patient remained deeply comatose during this time. The patient's stay in the ED was charted by the staff at 1100, 1245, 1340, 1400, 1415, 1445 and 1530 when a CT scan of the brain was finally ordered

and performed. It is very concerning that, despite the charting and recording of the patient's poor neurological condition, no further action was done until very late.

The neurosurgical team responded promptly. An urgent craniectomy and evacuation of the acute subdural haematoma was performed. There is no indication that an Intracranial Pressure (ICP) monitor or an external ventricular drain was inserted. This may be because the brain was very swollen and the surgeon may have felt it necessary to perform a rapid closure before the brain became too swollen for the dura to be closed.

It would have been preferable to have an intracranial pressure monitor inserted for postoperative monitoring and management of the patient's raised intracranial pressure, although the assessor did not think that this would have made any difference to this patient's poor outcome.



NEUROSURGERY

Case 8: Postoperative patients need a care plan and timely investigation

Clinical details

This case is of a middle-aged patient with good grade subarachnoid haemorrhage secondary to a ruptured right Internal Carotid Artery (ICA) bifurcation aneurysm treated with microsurgical clipping. The patient did not recover from surgery and died three days later from cerebral infarction. The patient's clinical course is detailed below.

The patient presented with severe headache, nausea and vomiting, and had been suffering from headache for one week prior to presentation. Glasgow Coma Score (GCS) was 14/15 with no focal neurological deficit. Subarachnoid Haemorrhage (SAH) secondary to ruptured right ICA bifurcation aneurysm was diagnosed. An External Ventricular Drain (EVD) was inserted to relieve hydrocephalus.

The next morning, the patient underwent microsurgical clipping of the aneurysm. According to the operation report, there was intraoperative rupture with three minutes of temporary clipping to the ICA, Middle Cerebral Artery (MCA) and Anterior Cerebral Artery (ACA). The aneurysm was successfully clipped with a single fenestrated Sugita clip. It was documented in the operation report that a branch of the M1 was sacrificed. All major cerebral arteries were patent on intraoperative Doppler ultrasound prior to closure.

The patient arrived in Postanaesthesia Care Unit (PACU) at 1320. The neurological state was recorded as GCS 6/15 (E1, V1, M6) with left hemiplegia. This only improved to GCS 8/15 at 1400. Postoperative Computed Tomographic Angiography (CTA) was not done until 1606 and did not show a postoperative haematoma or vasospasm. The patient arrived back on the ward at 1730. The condition remained unchanged. There was no documentation as to the cause of the patient's poor state or management plan. During the night, the patient's right thigh was noted to be twitching. This was presumed to be a focal seizure and the patient was given 0.25 mg clonazepam intravenously at 0030 and again at 0140 by the Night Cover. The second dose was given after consultation with the Neurology registrar. The Neurosurgery registrar appeared to be aware but it was unclear at what stage they were informed.

The next morning, a Medical Emergency Team (MET) call was made when the patient became more unresponsive. An urgent Computed Tomography (CT) showed a new frontal Intracerebral Haemorrhage (ICH) (2.4x3.2cm) and severe swelling, with mass effect of 2 cm of midline shift. The patient underwent urgent decompressive craniectomy, and evacuation of extradural, subdural and temporal lobectomy, according to the operation report. Following this, the patient remained intubated in the Intensive Care Unit (ICU), GCS was 3/15 and only withdrawing to pain in feet.



Intracranial Pressure (ICP) was controlled for the next 24 hours. Patient then developed acute increased ICP with blown right pupil. An urgent CT showed a right MCA, right posterior cerebral artery and bilateral ACA infarction with oedema and mass effect. This was deemed to be caused by cerebral vasospasm. Attempt was made to arrange a cerebral angiogram and endovascular intervention but this was not available at the time. Within 30 minutes of deterioration the patient had bilateral fixed and dilated pupils. After discussion with the patient's family, treatment was withdrawn and the patient was palliated.

Comments

The patient did not regain the original preoperative neurological state after surgery. Given the time course and normal CTA, the most likely explanation would be an operative complication in which a significant arterial branch was taken leading to a stroke. This is a well-recognised major complication of microsurgical clipping associated with a significant mortality rate, even with intensive management. However, in this case, the management of this complication was inadequate and concerning.

Areas of concern include:

1. Delay in investigating postoperative neurological deficit. A CT scan of the brain was performed three hours after the patient arrived in recovery with neurological deficit. In any surgical case where there is postoperative deficit, investigation should be done urgently to rule out any reversible causes such as postoperative haematoma.
 2. Administration of intravenous clonazepam, a long acting benzodiazepine, in this patient could be considered a contraindication. Sedating a patient with intracranial pathology associated with raised ICP and low GCS is a very dangerous situation. It is a decision that should be made by a consultant. In addition, in this case, the indication for clonazepam was questionable. The symptom was mild and was on the wrong side. The decision appeared to have been made by the night cover (presumably a resident) but more concerning is that it was done in consultation with both the Neurology and Neurosurgery Registrars. It may have exacerbated the cerebral swelling and led to the deterioration on day one post operation. Admission to ICU post-clipping to optimise Blood Pressure (BP), oxygen saturation and ICP could have been beneficial in limiting the extent of infarct.
- The lack of interventional radiology raised by the first-line assessor is certainly an issue in the management of vasospasm. However, in this case, it would not have changed the outcome. The primary pathology here is postoperative stroke and subsequent cerebral oedema leading to further ischemia rather than vasospasm.
- When an operative complication occurs, it needs to be acknowledged and measures taken early to prevent or limit its sequelae although, in this case, the final outcome may not have been preventable.



ORTHOPAEDIC SURGERY

Case 9: Allow time for preoperative assessment

Clinical details

This is the case of an elderly patient who underwent an elective Total Hip Joint Replacement (THJR). The patient was assessed by the hospital Pre-Admission Clinic (PAC) and then admitted the day before surgery for an anaesthetic review prior to surgery. The patient was graded with an American Society of Anesthesiologists (ASA) score of 2 and judged appropriate for surgery, although the exact level of risk according to the anaesthetist was not recorded. The patient underwent an uneventful and routine THJR the next day. The surgery took approximately 80 minutes and, other than some transient episodes of hypotension during the procedure, the patient had no obvious anaesthetic issues during the case.

During the first 48 hours after the surgery, the patient displayed several episodes of mild hypotension, treated with Intravenous (IV) fluids, and some confusion, particularly overnight. The patient also showed gradual deterioration in their oxygen saturation and was treated with nasal oxygen. Postoperative haemoglobin was 93 g/L and the patient was subsequently treated with two units of packed cells. The patient had some renal impairment during this time, with a marginal urine output and a creatinine of 153 $\mu\text{mol/L}$.

On the third day after surgery the patient had a sudden onset of throat tightness, wheezes and decreased oxygen saturation which led to a transfer to the Critical Care Unit (CCU) for further treatment and monitoring. The patient was subsequently diagnosed as having had an Acute Myocardial Infarction (AMI) and was worked up by the cardiology unit. The patient developed gradually worsening Atrial Fibrillation (AF), hypotension and cardiac failure and then developed possible pneumonia and sepsis. Renal function also gradually deteriorated and a family meeting was held to discuss the patient's prognosis. After this meeting, a decision was made to provide palliative treatment only and the patient passed away 12 days after surgery.

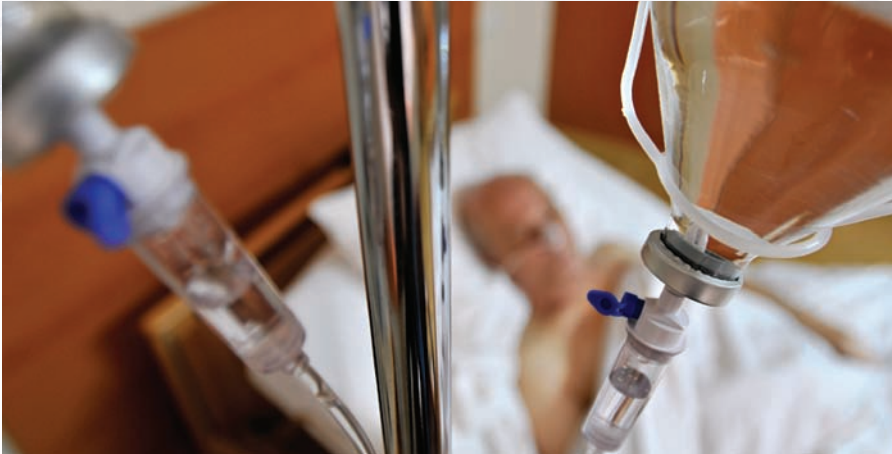Comments

There are two possible areas for consideration in this case, both of which relate to the preoperative assessment of this patient. The management of this patient over the time of surgery and in the postoperative period was difficult due to the age and medical comorbidities but, overall, was adequate and appropriate. Firstly, it is not clear if the patient was medically assessed at the PAC. A referral to a cardiologist for assessment probably would have been appropriate and may have reduced the risk of this outcome. Secondly, the preoperative anaesthetic assessment occurred the day before surgery and after



the patient had been admitted for surgery. This assessment may have been more appropriately carried out earlier as part of the PAC to enable the opportunity for the anaesthetist to arrange further preoperative investigations and opinions, such as a cardiology review.

The anaesthetist may have felt pressured not to do this if the assessment occurred the day before surgery when the surgical team and, more importantly, the patient were otherwise fully prepared to proceed.





ORTHOPAEDIC SURGERY

Case 10: Delay in diagnosis of fractured neck of femur can be fatal

Clinical details

This very elderly patient presented to an Accident and Emergency Department (A+ED) following an unwitnessed fall. The patient complained of right hip pain and was unable to walk. Plain x-rays of the pelvis and hip did not show a fracture. The patient was discharged back to a high-level-care nursing home and, because of ongoing pain and immobilisation, the patient was returned to hospital one week later. Further x-rays, including a Computed Tomography (CT) scan, showed a subcapital fracture of the neck of the right femur. The patient was on clopidogrel and there was a delay in being able to operatively treat the fractured neck of femur for five days. It was decided to treat the fracture with a Moore's unipolar hemiarthroplasty. After reaming, the Moore's prosthesis was not able to be inserted. A decision was made to change to a cemented Unitrax Exeter femoral stem. In the process of passing a plug down the femoral canal to block the passage of cement distally, the patient developed significant bradycardia and, subsequently, a cardiac arrest. The patient was resuscitated intraoperatively and the wound closed, leaving the patient with, in effect, an excisional arthroplasty of the hip. The patient's condition continued to deteriorate and they died fairly soon afterwards.

Comments

It is evident that, on the initial presentation, the patient clinically had a fracture of the neck of the right femur. The Casualty resident noted that the patient had pain when rotating and abducting the hip. A so-called normal initial x-ray does not exclude a fracture of the hip. It is most likely that there was an undisplaced subcapital fracture of the neck of the right femur present. This was clinically confirmed by the fact that the patient had ongoing pain and failed to mobilise.

On re-presentation one week later, it was commented that there was a subcapital fracture of the neck of the right femur noted on x-rays and CT scanning. In the documentation, however, there was very little evidence in relation to whether or not this fracture was displaced or undisplaced. There is one comment about impaction of the fracture. The patient was assessed preoperatively from both a medical and also an anaesthetic point of view. The regular medication of clopidogrel was the major factor for delay in having operative treatment of the hip fracture. The treating orthopaedic team identified the patient to be of a small build and to have a small femur and pelvis on radiological investigation. It was decided to carry out a Moore's hemiarthroplasty. This was, presumably, on the basis that the patient walked minimally and had a displaced subcapital fracture of the neck of the right femur.



It is very difficult to template x-rays in relation to the use of a Moore's prosthesis. The current use of computerised x-ray systems also makes it very difficult to template prostheses. Intraoperatively, the Moore's prosthesis could not be seated. It was decided to use an Exeter type small stem to circumvent the problem. The equipment required for the Exeter prosthesis was not open and available at the time. It had to be retrieved from the theatre storeroom and opened. Clearly, this added time to the length of the surgical procedure and it is probable, as is often the case after a period of fasting and intraoperative blood loss that around this time the patient was relatively under-volumed. The procedure of passing a femoral plug down a tight canal is equivalent to passing a nail. It would seem that this procedure resulted in some sort of embolic phenomenon that resulted in cardiovascular collapse. The other possibility in this patient is that a pulmonary embolism occurred, subsequent to the fracture sustained twelve days prior to surgery, as the patient had been in bed during this time. Initial resuscitation was successful, but postoperatively, the patient deteriorated quickly and died.

1. The decision to discharge the patient on the first attendance without adequately radiologically excluding a hip fracture was incorrect. The casualty resident made the diagnosis clinically. We need to remind ourselves that diagnoses in medicine and surgery are based on history and

examination. Radiological investigations may be confirmatory of the clinical diagnosis.

2. The use of an irreversible antiplatelet agent disrupted the appropriate management of the patient. One needs to ask whether or not an elderly patient should be on an irreversible antiplatelet agent versus aspirin etc. It is clear, from every bit of scientific literature, that it is imperative that patients with fractures of the neck of the femur should be treated operatively as soon as possible to minimise complications and, ultimately, the death rate from the procedure.

3. Unfortunately, there is insufficient information to know whether or not the subcapital fracture of the neck of the femur was significantly displaced. If there was complete displacement, that is, a Garden III or Garden IV fracture, then excision of the femoral head and hemiarthroplasty, either via a Moore's prosthesis or cemented unipolar hemiarthroplasty, is appropriate. Although traditionally the Moore's prosthesis has been used in patients who are relatively immobile or thought to have a limited life expectancy, its regular use is decreasing. If the subcapital fracture is undisplaced or minimally displaced, then one surgical option is to consider fixation with a hip screw or cannulated screws. This is a less invasive procedure, that is, it does not open up the hip joint and expose the patient to all the risks of partial or total hip arthroplasty.



Some surgeons, if the patient is able to have a general anaesthetic, would be happy to carry out this procedure soon after the fracture in the setting of a patient on clopidogrel. As outlined above, templating of x-rays in relation to prostheses is not easy. The almost rampant rush towards digital radiology has made templating in relation to osteoarthritis of the hip and hip fractures very difficult.

There are no consistent software applications available in relation to templating. Given that the relatively small size of the patient was recognised, one might argue that, in hindsight, it would have been sensible to have the Exeter system open on the operating table as a backup. In the practical world, it means that there will be a lot of equipment open and not every theatre nurse would be familiar with all aspects of both systems.

Earlier diagnosis, less operative delay and a wider inventory of intraoperative equipment may have led to a better clinical outcome, but given that the patient was very elderly and did have a history of a previous transient ischaemic attack and possible heart disease, the potential of significant complications and even death were high at the time of admission.

It would be of benefit to highlight to the resident medical staff in A+ED that if an elderly patient is admitted following a fall, unwitnessed or witnessed, has pelvic, groin, and lower limb pain and is unable to walk, it should be assumed that they have a fractured neck of femur until proven otherwise. A so-called normal plain x-ray of the pelvis and hip does not exclude the diagnosis of a fracture of the neck of the femur.



ORTHOPAEDIC SURGERY

Case 11: Patient care postoperatively

Clinical details

The case is that of a home-dependent elderly patient on home oxygen due to emphysema. The patient was also on warfarin for two previous spontaneous pulmonary emboli. The patient was admitted through emergency following a fall at home, while making a bed, where the patient sustained a right hip fractured neck of femur.

A right hemiarthroplasty was performed the next day, after reversal of the patient's warfarin, and this was quite appropriate. The patient had a very complicated postoperative course, suffering from rapid Atrial Fibrillation (AF), bilateral pleural effusions and oxygen dependence, fluid overload, pseudo obstruction and excessively high International Normalized Ratio (INR) despite warfarin being withheld, and hypernatremia.

The patient was co-managed with various appropriate clinical teams but, unfortunately, continued to deteriorate; two weeks postoperatively, the decision was made, in conjunction with the family and the palliative care team, to palliate and the patient finally died.

Case Notes

The hospital case notes provided are adequate, with good documentation of the sequence of events and measures taken. The case was not referred to the Coroner, nor was a postmortem required.

Comments

1. Preoperative assessment, decision to proceed, choice of surgical procedure and conduct of surgery

The preoperative assessment was adequate and the decision to proceed, choice of surgical procedure and conduct of surgery was quite reasonable. This patient had significant medical problems, particularly pertaining to their age, respiratory status and anticoagulation. My only comment would be that the patient may well have benefitted from a High Dependency Unit (HDU) bed postoperatively as the patient had minimal reserve and strict fluid balance and monitoring was paramount.

2. Adverse event

There were multiple adverse events, as follows. It appears this patient went into rapid AF on day one postoperatively and also had large bilateral effusions which were treated with Lasix and antibiotics. I could find no formal medical review other than that of the orthopaedic team. The patient did improve, but day three post operation a Medical Emergency Team (MET) call occurred where the patient was reviewed by both medical and Intensive Care Unit (ICU) teams. The rapid AF was finally treated with digoxin.

Day four post operation, the patient developed pseudo obstruction and was reviewed by both the cardiology and general surgical teams. The warfarin was appropriately withheld and the patient was



treated with Intravenous (IV) fluid and a Naso-Gastric (N/G) tube.

Day six post-operation, blood was noted in the Naso-Gastric (N/G) tube and was thought to be due to a traumatic insertion. IV pantoprazole was commenced and, due to ongoing abdominal distension, the general surgical team referred the patient to the gastroenterology team.

Hence, day seven post-operation, the patient underwent an endoscopic decompression by the gastroenterology team. The patient was commenced on clear fluids the next day but noted to have an INR of 5.7 on day nine, despite the warfarin being withheld five days prior. The patient was also noted to have sodium of 157 mmol/L on day ten post-operation and was reviewed by the haematology team on day eleven with regards to the high INR. This had been reversed with vitamin K and was attributed to the patient's prolonged fasting status, inadequate intake of vitamin K and a possible side effect of the antibiotics that the patient was on.

Day twelve post-operation, the patient was reviewed by the ICU team again because of marked tachypnoea and the patient was considered to be overloaded. The patient had another MET call on day thirteen post-operation where the patient was found on the floor. The patient's sodium was 160 mmol/L but the patient was saturating adequately at 90% on two litres. Day fourteen post-operation, the patient was reviewed by the respiratory team because the patient was in type two respiratory failure with

carbon dioxide retention. Unfortunately, the patient couldn't tolerate Biphasic Positive Airway Pressure (BIPAP) and more Lasix was given.

Day fifteen post-operation, the patient was deteriorating further and a decision was made to involve the palliative care team, who consulted the patient and the patient's family, and it was agreed to palliate the patient; the patient finally died from respiratory failure.

3. Areas of concern

The major area of concern was that there was no consistent plan outlined with regards to the patient's fluid management. Admittedly, it was an extremely difficult problem to manage, being hypernatremic but also being fluid overloaded. The patient had pleural effusions which were not drained and the patient had little respiratory reserve. The mainstay of the IV therapy was crystalloid solution with minimal colloid and there was no mention as to the patient's albumin or protein levels. Pathology was also not available within the notes. Strict fluid balance charting was inadequate and there were no daily weights clearly recorded.

This patient was extremely difficult to manage postoperatively and may well have benefitted initially from HDU care. It did not appear as though there was a consistent medical team involved daily with the patient management, from which the patient may well have benefitted. It is unclear whether this would have changed the overall outcome, however.



GYNAECOLOGICAL/VASCULAR SURGERY

Case 12: Inability to contact on-call surgeon

Clinical details

The patient was a woman who was admitted to hospital with symptoms and signs of a tubal ectopic pregnancy, namely, six weeks amenorrhoea, an elevated Human Chorionic Gonadotropin (HCG), an ultrasound which showed an empty uterus, an adnexal mass and some free fluid. Arrangements were made for her to undergo laparoscopic surgery to deal with the ectopic pregnancy.

The operation commenced at approximately 2200. A Verress needle was inserted at the umbilicus to obtain the pneumoperitoneum. It was recorded that the patient was thin. After inserting the Verress needle, the intra-abdominal pressure, which was initially 5 mm, fell to 0 mm Hg and remained low. The abdomen became tightly distended. A 10 mm trocar was then inserted at the umbilicus and, when the laparoscope was inserted, the abdomen was noted to be full of blood. Also another 5 mm port was inserted in the left iliac fossa. A decision was made to do an immediate laparotomy, initially through a Pfannenstiel incision which was converted to a midline incision above the umbilicus. Aortocaval compression was applied. The help of the surgical registrar, general surgeon, vascular registrar and gynaecological consultant was also sought. The vascular surgeon on call was not contactable; however, other

vascular surgeons at the hospital were called and one responded.

The general surgeon extended the incision to the xiphisternum. The bleeding was initially controlled by pressure to the site of the vascular injury for 15 minutes; then the general surgeon attempted to repair the vascular injury, which was thought to be venous. Cardiopulmonary Resuscitation (CPR) commenced at about 10 minutes into the operation, with blood transfusion and Intravenous (IV) fluids given by the anaesthetist.

The operation notes indicate "likely trochar injury to major vessels-vigorous bleeding from near iliac bifurcation". Attempts to oversew achieved only partial control of the bleeding, which was mostly controlled by pressure.

The vascular surgeon arrived nearly an hour into the operation and repaired arterial bleeding from the right iliac artery near its origin. They noted that the general surgeon had already repaired an iliac venous injury. She was very coagulopathic ++ by this time. Local pressure assisted haemostasis. During this time, the patient remained on CPR.

CPR ceased when the patient was in asystole. She was given defibrillation, calcium and adrenaline to no avail and was pronounced dead soon after.



Comments

First Gynaecological Review

1. Adverse event

This was clearly an unintended and unexpected adverse event which occurred in a young, fit patient undergoing surgery who would have been expected to survive.

2. Areas of concern

There are several areas of concern:

- Use of the Verress needle vs. Hasson cannula. There is ongoing debate about the best method of obtaining a pneumoperitoneum for laparoscopy. Most gynaecologists prefer to use the Verress needle inserted through the umbilicus. General surgeons, on the other hand, tend to prefer to use the Hasson cannula and perform an open laparoscopy. Patients who are thin are at increased risk for vascular damage to aorta, Inferior Vena Cava (IVC) and iliac vessels. So this thin patient was at increased risk for vascular damage. It is not absolutely clear which instrument caused the damage, but in my opinion, it may well have been both as there seem to be two separate injuries noted by the vascular surgeon - one venous by the Verress needle and the other arterial by the 10 mm trocar. The drop in the intra-peritoneal pressure occurred immediately after insertion of the Verress needle; could this have been as a result of gas embolism when the Verress needle entered the iliac vein?

- Seniority and availability of senior surgical staff. There was lack of timely involvement by experienced staff. The laparoscopy was performed by a senior gynaecological registrar who would be expected to have been competent and able to deal with an unruptured tubal ectopic pregnancy. It appears that attempts were made to contact the on-call vascular surgeon who was not immediately contactable.
- Method of vascular repair. Compression and packs seemed to be only partly successful in controlling the bleeding. Clamping of the aorta would have been preferable to pressure before any attempt to directly suture the damaged vessels, especially when arterial damage was a distinct possibility.

3. Level of care

Apart from the surgical technique for laparoscopic entry in this thin patient, the level of care was in line with current practice. Most gynaecologists would have operated on an unruptured tubal ectopic pregnancy laparoscopically using the Verress needle to obtain the pneumoperitoneum. With the benefit of hindsight, a direct entry would have been preferable in this thin patient. Alternatively, there should have been a modification of the technique, with more elevation of the abdominal wall (thereby further away from the major blood vessels) and using a more oblique entry with the Verress needle. The Gynaecology Registrar probably made an error of surgical judgement and did not appreciate how very



close the major vessels were to the surface of the abdominal wall in this thin patient.

4. Constructive comments

The Verress needle is the instrument preferred by most gynaecologists for obtaining a pneumoperitoneum. Debate should be re-opened regarding the uncritical use of the Verress needle by gynaecologists for all laparoscopies. Damage to large vessels and/or viscera is slightly more common with the Verress needle technique than with the Hasson, or open entry, technique. Most gynaecologists have only been trained to use the Verress needle. They are usually not familiar with, or trained to use, an alternate method such as open entry for more high-risk cases, for example, thin patients and/or those who have had previous open abdominal surgery. Gynaecologists should be trained to use more than one method to obtain a pneumoperitoneum and select the method which is most appropriate to the individual patient.

Vascular Review

Exsanguination from laceration of major retroperitoneal vessels, and its avoidance and control, are well known to all laparoscopists, gynaecological and others. A senior gynaecological registrar should be capable of avoiding and of controlling this event, or not have been entrusted with operating unsupervised on such a tubal pregnancy; limited control by pressure over the bleeding site was achieved. A consultant

general surgeon should be capable of controlling the aorta with a vascular clamp and then either suturing the laceration or calling for help; arterial control was not achieved before attempting to suture.

1. Preoperatively

Laparoscopy began nine hours after the patient's arrival in the Emergency Department (ED) with obvious clinical features of tubal pregnancy. An earlier start, in daytime, might have found more consultants accessible and more support for the gynaecological registrar operating. Patient observations in ED and ward, tests and ultrasound imaging, IV fluid therapy and Anaesthetist Assessment (ASA 1) were all satisfactory. No consultant involvement is recorded. Consent was duly signed, for "Laparoscopic/Laparotomy +/- Salpingectomy - Right side - for ectopic gestation," with specific risks noted as: "Infection, Bleeding, Damage vital organs".

2. Operation

There are separate operation reports written by the gynaecological registrar and vascular surgeon, separate page notes by the general surgeon and vascular registrar, and a further page by the gynaecological team. The anaesthetic chart provides details of the collapse, times and CPR. A progress page added later by the gynaecological registrar revises the original operation note "post discussion of events", and describes technical difficulty with the tested Verress needle (single pass, NB thin patient) and



inflation measurement, despite tight gaseous abdominal distension, resulting in a change of technique to trocar at the umbilicus. The gynaecological consultant provided the e-deposition to Coroner.

The technique for inducing pneumoperitoneum by needle or trocar is well-studied (see current guide from the Victorian Surgical Consultative Council (VSCC) and evidence from Australian Safety and Efficacy Register of New Interventional Procedures–Surgical). Thin patients are at particular risk of injury to major retroperitoneal vessels with whatever sharp instrument is used, and this patient's anterior abdominal wall was obviously inadequately elevated before entry of needle and/or trocar.

3. Response to iliac vessel injury

The patient's bleeding was recognised via the laparoscope 15 minutes into the operation; an LIF port was inserted, and the response to circulatory collapse was prompt conversion to open laparotomy (Pfannenstiel incision, predictably inadequate, was extended by midline incision to above the umbilicus). Aortocaval pressure appropriately limited the bleeding from iliac vessels, so 20 minutes of CPR, Damage Control Resuscitation (DCR), fluids and vasopressor enabled spontaneous heart circulation to resume. Consultant help was sought.

4. Vascular surgeon not able to be contacted

The vascular surgeon rostered on call had arranged a substitute, unbeknownst

to switchboard and theatre. Neither was immediately contactable, so a general surgeon was sought. Meanwhile, the operating registrar had attempted more than once to oversee the presumed venous bleeding site, but it was still only partly controlled by packs and pressure. The patient remained stable. An Indwelling Catheter (IDC) was inserted by the resident. The gynaecological consultant arrived. The vascular registrar attended and scrubbed in, having located a vascular surgeon.

The general surgeon removed packs and attempted 0-Prolene oversewing sutures about half an hour into the surgery with continued bleeding, asystole recurred and persisted until death, despite CPR. Proximal aortic control by clamping would have been standard and prudent. One must hope that suitable vascular clamps and more precise suturing are available in such a teaching hospital.

A vascular surgeon arrived during the final asystolic episode and repaired the lacerated iliac artery, but to no avail. The diagram of the injury shows a rounded laceration at the origin of right common iliac artery (not the iliac bifurcation) where it crosses the left iliac vein and caval confluence, usually midline at the level of the umbilicus. This is consistent with a vertical puncture by the umbilical trocar.

5. Anaesthetic considerations

The anaesthetist's response to bleeding and both arrests was prompt. Anaesthetic was



endotracheal with a cubital cannula and Non-Invasive BP monitoring (NIBP). Then, a 16G external jugular vein catheter was added and a brachial arterial line attempted, but there was no pulse and no ultrasound to guide (“available later”). Coagulopathy developed. IV 4.5L crystalloid and colloid, 24 packs red cells, 12 units cryoprecipitate, 4 units Fresh Frozen Plasma (FFP), and 1 unit platelets were given. It is not clear what help the anaesthetist received. CPR was then ceased.

6. Coroner e-deposition

This omits reference to who was operating or who supervising when the injury occurred, and describes the salvage attempts but not the cause. The case notification is no more insightful; question 15 is quite inadequately answered. There is no autopsy report from the Coroner’s pathologist, and this must be obtained.

7. Evidence and practice guidance

The second-line assessor comments on gynaecologic training being unreasonably restricted to the Verress needle technique of inducing pneumoperitoneum. Trainees in laparoscopy should experience several methods and select the most appropriate to the individual patient. Current evidence on risk of major vascular or intestinal damage during laparoscopy shows no entry technique any less risky than any other (Australian Safety and Efficacy Register of New Interventional Procedures–Surgical review of high-level evidence). The VSCC

developed a Clinical Practice Guide—“Laparoscopic Vascular Injuries”—in June 2010, which was circulated to all surgeons in Victoria, including gynaecologic surgeons and their trainees, and is available on the VSCC website. Thin patients especially require elevation of the anterior abdominal wall to avoid laceration of the major retroperitoneal vessels, and it’s vital how the sharp instrument is used rather than whether Verress, Hasson or any other is selected. The management of the emergency, should it occur, must be well-rehearsed, in simulation or during open laparotomy or autopsy.

General surgeons must be able to dissect and obtain proximal control of a bleeding artery in the trunk, or pack an injured vein, and attempt controlled suturing, unless someone more adept at vessel repair can be summoned. Suitably experienced specialists; appropriate supervision of trainees; better theatre access for emergencies; surgeon contactability; vascular clamps and sutures; anaesthetic equipment maintenance and support in theatre; and more autopsies for precise diagnosis, feedback and training of clinicians are further areas of concern raised by this tragic and unnecessary outcome.



Second Gynaecological Review

1. One of the factors responsible for large vessel injury is lateral deviation of the needle or trocar at the time of insertion. This can be a particular problem in thin patients. When the instruments are inserted from the patient's left side, which is usual, the vascular injury can more usually involve the right common iliac artery and the left common iliac vein close to the bifurcations. This was the injury sustained in this particular case.
2. The lack of immediate back-up from more senior and experienced surgical staff (and possibly extra anaesthetic staff) appeared to be a factor in the unfortunate train of events.
3. When the massive haemorrhage was realised and the abdomen was opened, the bleeding was controlled by pressure. This allowed resuscitation of the patient and stabilization of her condition. This is evident from the operation notes and the anaesthetic chart. The vascular surgeon was not quickly available and the general surgery team arrived and attempted repair of the injured vessels before clamps were applied to prevent further major blood loss (e.g. aorta clamp). This resulted in massive blood loss for the second time, an event from which she did not recover. The comments and recommendation of the gynaecological and vascular reviewers appear to be reasonable and constructive.



VASCULAR SURGERY

Case 13: Beware of ceasing anticoagulation in high embolic risk patient

Clinical details

This patient was admitted under the Vascular Unit with acute ischaemia of the right upper limb in the background of coronary artery bypass surgery followed by atrial fibrillation, multiple cerebral strokes leaving the patient with weakness down the right side, and significant urological bleeding resulting in falls and hypotension which necessitated stopping warfarin. The patient was also in hospital for investigation of the urological bleeding.

While in hospital, the patient underwent brachial embolectomy. The patient had planned urological surgery delayed due to a high International Normalised Ratio (INR). In preparation for this procedure, both at the time of delay and when it finally went ahead, all anticoagulation therapy was stopped.

Following the urological surgery, the patient developed further right lower limb ischaemia and embolectomy was again required.

Following these procedures, the patient initially did well but because of difficulty with mobility, developed a chest infection, which was adequately treated, and subsequently developed a myocardial infarction and pneumonia, which were the terminal events.

Comments

The case notes provided an adequate record of the patient's course in hospital for this procedure, as well as an adequate record of previous hospitalisations. It confirmed the necessity to cease the warfarin due to excessive blood loss prior to admission and it also confirmed that prior to starting warfarin, the patient had multiple cerebral infarcts. The patient was obviously at considerable risk given the past history and comorbidities.

Review of the history shows that this patient underwent vascular surgical procedures in a timely manner and they were carried out by appropriately qualified surgeons.

The delay in the surgical procedure to be carried out by another discipline resulted from the patient's INR being high on the day of surgery, leading to cancellation. This, unfortunately, meant that complete cessation of all anticoagulation treatment was required on more than one occasion. There was no documentation that the patient was looked after in the High Dependency Unit (HDU). Had this occurred, there is a possibility that the initial postoperative chest infection may have been recognised and treated earlier.

The areas of concern raised by first-line assessment were:

1. The delay in surgery for urological bleeding at a time when the patient was off all anticoagulation. There is no doubt that



this led to a second embolus to the right leg requiring a further surgical procedure. This patient had a well-documented history of embolic events, requiring anticoagulation at all times. There is no indication in the history that the urological unit understood the significant nature of this patient's risk.

2. That this patient developed a chest infection postoperatively was not unexpected given the past history of multiple strokes and the other comorbidities. The final event was the development of Non-ST Segment Elevation Myocardial Infarction (NSTEMI), with a marked increase in troponin level, and subsequent pneumonia development. Palliative measures were undertaken after this occurred, which was appropriate.

This patient's progress illustrates the problem of cessation of anticoagulation in a patient who has had multiple embolic episodes while not anticoagulated. Unfortunately, complete cessation is unavoidable under some circumstances, especially where significant bleeding is occurring and where particular operative treatments are required, for example, the urological surgery.

It is up to the surgical units and hospitals to be aware that unnecessary delays in treatment are catastrophic for patients such as this and this patient illustrates that very well.

It may be that hospitals should have a method of prediction of thromboembolic risk for patients when they are off anticoagulation.

This patient's postoperative course was almost inevitable given the comorbidities and multiple surgical procedures. It may be that a short period of time in HDU may have recognised the early stages of chest infection and instituted treatment prior to the fourth postoperative day. Once the chest infection had occurred, because of this patient's immobility and co-morbidities, it was difficult to obtain a good outcome.



VASCULAR SURGERY

Case 14: Second look laparotomy after Inferior Mesenteric Artery (IMA) bypass may be advisable

Clinical details

This elderly patient underwent a complex elective aorto-iliac reconstruction for aortic, bilateral common iliac and left internal iliac artery aneurysms. Under suprarenal cross clamp, a 16 x 8 mm aorto-right common iliac/left external iliac bypass was performed with ligation of left internal iliac aneurysm.

Right and left limb ischaemic times were 82 and 109 minutes respectively. Following completion of bypass graft, colonic ischaemia was detected. The Inferior Mesenteric Artery (IMA) was noted to be large and patent, although the degree of back flow was not commented upon. An IMA bypass was performed under seven minutes of suprarenal cross clamp, resulting in a total gut ischaemia time of 122 minutes.

Total anaesthetic time was four hours with 1500 ml blood loss recycled by cell saver. Intraoperative, lactate was elevated to five and noradrenaline of 6 ug/min was commenced.

In ICU, the patient developed abdominal compartment syndrome and returned to theatre on the second postoperative day for laparotomy, whereupon the left colon from splenic flexure to rectum was noted to be ischaemic. A low Hartmann's procedure with left hemicolectomy was performed, but despite resection, the patient progressed to multi-organ failure and died.

Comments

The hospital notes provided were adequate, although it was unclear whether the initial aortic cross clamp was supra or infra-renal, and why a Teflon cuff was used for the proximal anastomosis. The degree of IMA back flow was not documented as this may influence the decision to revascularise the colon earlier rather than later, particularly in the setting where the left internal iliac artery aneurysm was planned for ligation.

A postmortem examination was performed but no report was provided. Of interest would be the patency of the IMA bypass, which was not commented upon in the second laparotomy report.

Despite IMA bypass, the demise of this patient resulted from colonic ischaemia producing irreversible multiorgan failure. There are three possible scenarios. First, the bypass performed was delayed, and bowel infarction was already in progress. Second, the bypass occluded during the interval period. Third, the resection of ischaemic gut was delayed.

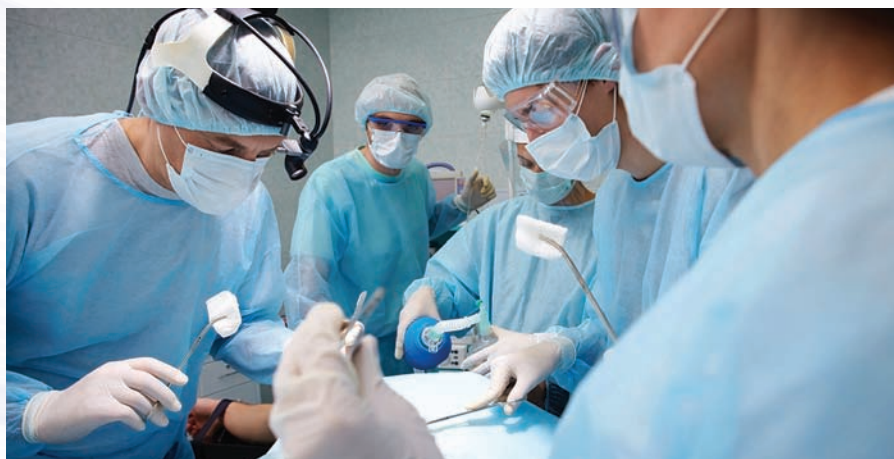The first factor can be improved by performing the IMA bypass prior to the distal iliac anastomosis, thereby reducing colonic ischaemic time. The assessor acknowledges that this is not the standard approach but can be considered in the setting of adjunctive left internal iliac ligation that increases the risk of pelvic ischaemia.

The latter two factors can be addressed by a planned second-look laparotomy within

24 hours following the initial procedure. This would detect an occluded IMA graft as well as provide an opportunity for earlier bowel resection before the onset of irreversible multiorgan failure.

In the setting where there is a large patent IMA with slow back flow, IMA revascularisation is mandatory. Usually, this is performed after

completion of aorto-iliac reconstruction but can be performed immediately after the proximal aortic anastomosis, thereby reducing colonic ischaemic time. A planned second-look laparotomy within 24 hours should be performed if bowel viability is questionable, thus providing the opportunity to resect infarcted gut.





LIST OF SHORTENED FORMS

A+ED	Accident and Emergency Department	ICU	Intensive Care Unit
ACA	Anterior Cerebral Artery	IDC	Indwelling Catheter
AF	Atrial Fibrillation	IMA	Inferior Mesenteric Artery
AFC	Association Française de Chirurgie	INR	International Normalised Ratio
AMI	Acute Myocardial Infarction	IV	Intravenous
ASERNIP-S	Australian Safety and Efficacy Register of New Interventional Procedures-Surgical	IVC	Inferior Vena Cava
ASA	American Society of Anesthesiologists	LAD	Left Anterior Descending (artery)
BP	Blood Pressure	LBO	Large Bowel Obstruction
CABG	Coronary Artery Bypass Graft	LIF	Leukaemia Inhibiting Factor
CCF	Congestive Cardiac Failure	LV	Left Ventricle
CCU	Critical Care Unit	MCA	Middle Cerebral Artery
CPR	Cardiopulmonary Resuscitation	MET	Medical Emergency Team
Cr-POSSUM	Colorectal Physiological and Operative Severity Score for the enumeration of Mortality and Morbidity	N/G	Naso-Gastric
CT	Computed Tomography	NIBP	Non-Invasive Blood Pressure
CTA	Computed Tomography Angiography	NSTEMI	Non-ST Segment Elevation Myocardial Infarction
DCR	Damage Control Resuscitation	OR	Operating Room
ED	Emergency Department	PAC	Pre-Admission Clinic
ERCP	Endoscopic Retrograde Cholangiopancreatography	PACU	Post Anaesthesia Care Unit
EVD	External Ventricular Drain	PCA	Patient Controlled Analgesia
FFP	Fresh Frozen Plasma	QP	Qualified Privilege
GCS	Glasgow Coma Score	RIMA	Right Internal Mammary Artery
HCG	Human Chorionic Gonadotropin	RV	Right Ventricle
HDU	High Dependency Unit	SAH	Subarachnoid Haemorrhage
ICA	Internal Carotid Artery	TAP	Transverse Abdominis Plane
ICH	Intracerebral Haemorrhage	THJR	Total Hip Joint Replacement
ICP	Intracranial Pressure	TURP	Transurethral Resection of The Prostate
		VSCC	Victorian Surgical Consultative Council



NOTES





CONTACT DETAILS

Victorian Audit of Surgical Mortality (VASM)
Royal Australasian College Of Surgeons
College of Surgeons' Gardens
250–290 Spring Street
East Melbourne VIC 3002 Australia

Web: www.surgeons.org/vasm

Email: vasm@surgeons.org

Telephone: +61 3 9249 1153

Facsimile: +61 3 9249 1130

Postal address:

Victorian Audit of Surgical Mortality (VASM)
GPO Box 2821
Melbourne VIC 3001 Australia

COLLABORATORS



The Victorian
Surgical Consultative Council

The information contained in this case note review booklet has been prepared by the Royal Australasian College of Surgeons Victorian Audit of Surgical Mortality Management Committee, which is a declared quality improvement activity. The Australian and New Zealand Audit of Surgical Mortality, including the Victorian Audit of Surgical Mortality, also has protection under the Commonwealth Qualified Privilege Scheme under Part VC of the Health Insurance Act 1973.