

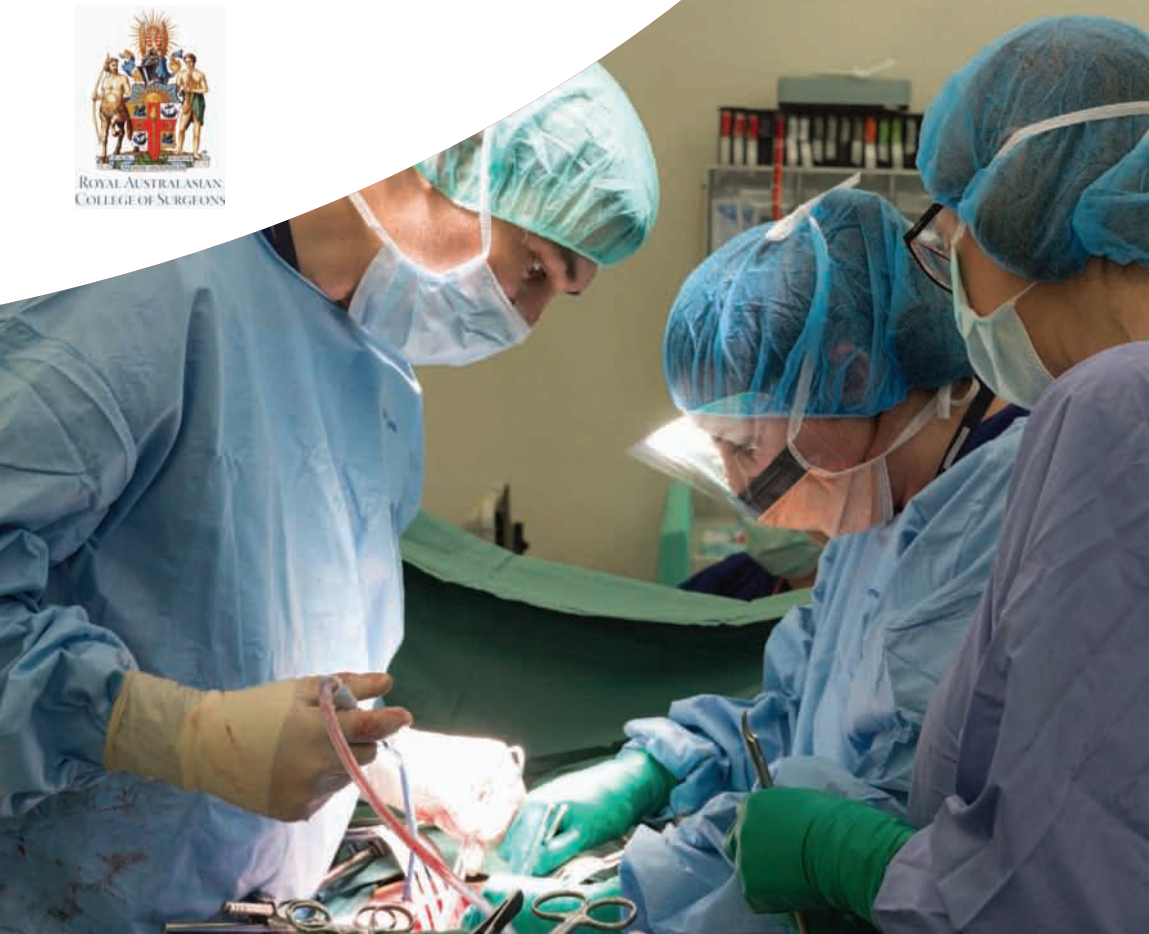Victorian Audit of Surgical Mortality (VASM)

Case Note Review Booklet

Eighth Edition - August 2016



ROYAL AUSTRALASIAN
COLLEGE OF SURGEONS



ROYAL AUSTRALASIAN
COLLEGE OF SURGEONS



Victorian Audit of Surgical Mortality



Australian and New Zealand
Audit of Surgical Mortality


The Victorian
Surgical Consultative Council



Department of
Health & Human Services



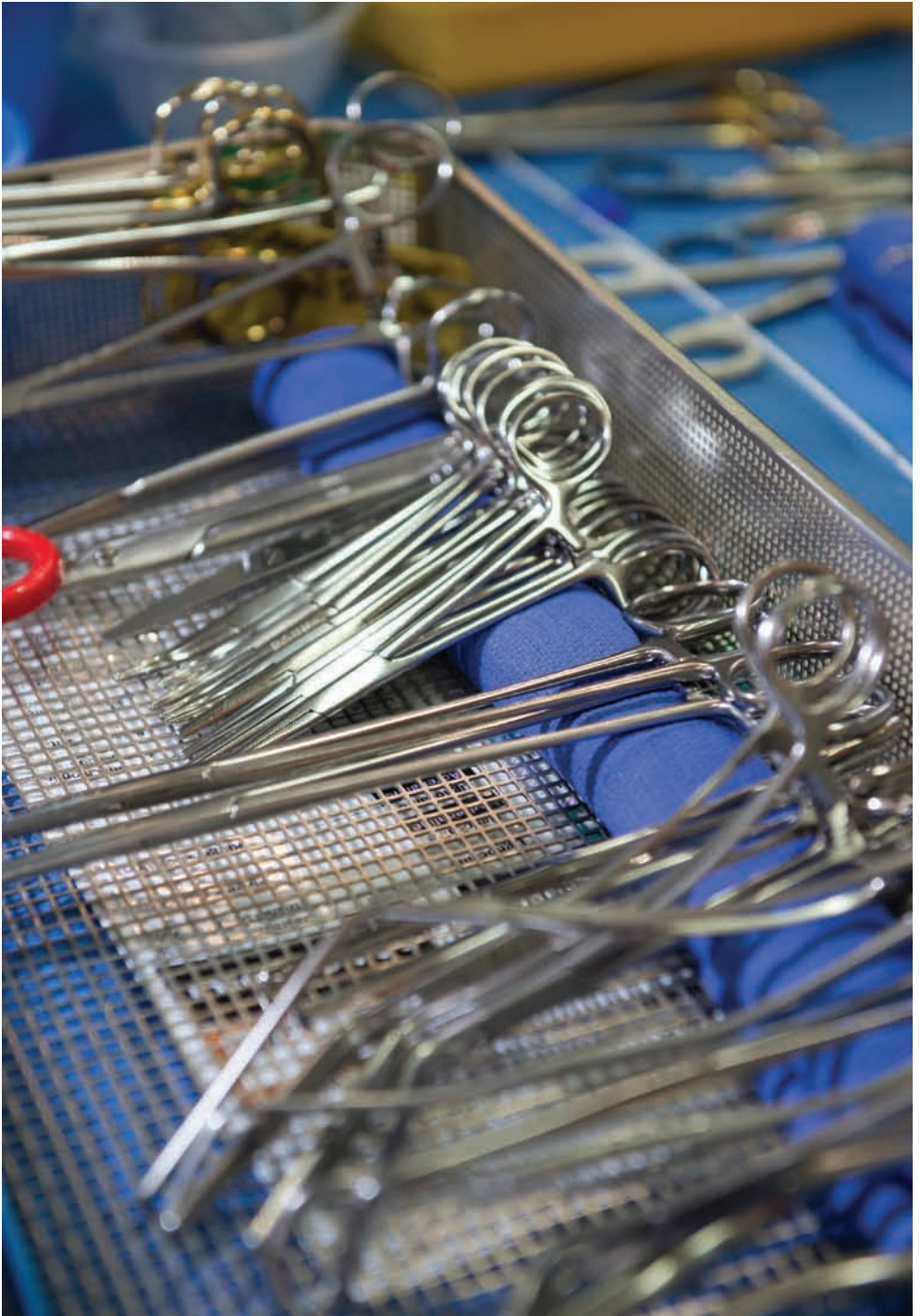
The Royal Australasian
and New Zealand
College of Obstetricians
and Gynaecologists





Contents

INTRODUCTION	3
EMERGING ISSUES AND RECOMMENDATIONS TO VASM CLINICAL STAKEHOLDERS	4
CARDIOTHORACIC SURGERY	6
Case 1: Delay in diagnosis of ischaemic bowel after cardiothoracic surgery; communication issues.....	6
CARDIOTHORACIC SURGERY	9
Case 2: Redo aortic valve replacement with postoperative haemorrhage; delay in return to operating room.....	9
GENERAL SURGERY	12
Case 3: Pancreatic malignancy with biliary and duodenal obstruction; communication issues	12
GENERAL SURGERY - BARIATRIC	14
Case 4: Gastric bypass with sepsis; nocturnal CT scan with aspiration in a patient requiring re-exploration instead of x-ray.....	14
GENERAL SURGERY	17
Case 5: Misdiagnosed postoperative complications after hemicolectomy	17
GENERAL SURGERY	20
Case 6: Colovesical fistula repair in a septic patient; when is a patient too ill for surgery?.....	20
NEUROSURGERY	22
Case 7: Hydrocephalus with delay to treatment and in response to postoperative complications.....	22
NEUROSURGERY	24
Case 8: High risk recurrent meningioma with intraoperative complications; is palliation the best option?.....	24
NEUROSURGERY	26
Case 9: Cerebellar AV malformation treated with both embolisation and excision; in which order should these be performed to reduce brainstem compression?.....	26
ORTHOPAEDIC SURGERY	28
Case 10: Palliative approach should be considered for a fractured neck of femur in a patient with terminal metastatic prostatic carcinoma	28
ORTHOPAEDIC SURGERY/ANAESTHETIC	30
Case 11: Vascular and bony complications after anterior approach for elective total hip replacement; steep learning curve for new surgical approaches.	30
ORTHOPAEDIC/VASCULAR/NEURORADIOLOGY	38
Case 12: Intracerebral embolus after fractured fibula due to paradoxical embolus without thromboprophylaxis	38
PAEDIATRIC SURGERY	39
Case 13: Misdiagnosis of Hirschprung's disease.....	39
UROLOGY	41
Case 14: Septic shock with delay in relief of urinary obstruction.....	41
VASCULAR SURGERY	43
Case 15: Delay in management of ischaemic leg; communication breakdown.....	43
LIST OF SHORTENED FORMS	45
VASM MANAGEMENT COMMITTEE MEMBERS	46
REFERENCES	46



Introduction

The audits of surgical mortality review deaths that occur while the patient is under the care of a surgeon in the public and private hospital sectors. As this peer-review process is intended as an educational exercise, we have selected a number of cases that bring out specific clinical issues. The cases do not necessarily relate to the period since the last booklet. They do, however, serve as topical and timely lessons for all surgeons and clinical team members. In successive years repeat issues of management appear. In particular: delay in diagnosis and treatment of the deteriorating patient and deficiencies in postoperative management. These are again highlighted in this eighth edition of surgical cases.

All cases selected have gone through a second-line assessment (case note review) by a Fellow from either the Royal Australasian College of Surgeons or the Royal Australian and New Zealand College of Obstetricians and Gynaecologists. The cases document critical incidents, often involving system issues rather than issues associated with the treating surgeon alone. The assessments have been edited to ensure that the patient, hospital, treating surgeon and assessor remain anonymous.

Qualified Privilege prevents us from sending assessment feedback to anyone other than the treating surgeon. This means that hospital management only receive indirect feedback on cases involving patients who died in their hospital. The surgeon can, of course, share the outcome of their assessment with relevant staff. Where there are obvious system issues it is important that hospitals are aware of, and subsequently address, the issues as appropriate. It is also important that the audit attempt to address emerging adverse trends.

Commencing with this edition, the lessons highlighted in each of the cases have been condensed at the end of some cases by the appropriate specialist serving on the management committee; their opinion and relevant literature references have been appended as “surgical lessons”. Case four also includes a unique Victorian Audit of Surgical Mortality (VASM) feature: the ability of the treating surgeon to provide feedback and insights after the assessment. Case 11 has an anaesthetic review because of the anaesthetic component in the death.

There are important lessons in this publication and we feel that it should be made available to all those responsible for delivering the care that resulted in the outcomes presented.

We also recommend the booklet be used as a teaching aid. Additional copies of this publication can be provided as necessary.

Audit staff would like to take this opportunity to thank all surgeons and hospitals participating in this educational activity. We hope you find this publication of value.

Mr Barry Beiles
Clinical Director, VASM

Emerging issues and recommendations to the VASM clinical stakeholders

Objectives to consider by hospitals and health professionals:

1. Improved leadership in patient care

- In complex cases there must be clear, demonstrable leadership in patient management.
- The treatment plan for each patient should be understood by all involved in the patient's care.
- The lead clinician must be accountable, responsive, prepared for challenges and must focus on optimal patient care.
- During lengthy operations there should be a low threshold for seeking assistance from colleagues to avoid fatigue.
- Senior surgical opinion is essential when dealing with surgical complications and should not be delayed by team hierarchy or structure.

2. Improved perioperative management

- Appropriate preoperative, intraoperative and postoperative preparation and management can decrease operative complications and promote successful recovery. Delay in, or unnecessary, preoperative investigations can have fatal consequences.
- Preparation and management should include:
 - evaluation of both physical and psychological preparation
 - complete medical history and physical examination procedures
 - consent for the surgery and discussion of potential outcomes
 - appropriate documentation and communication of results with clinical and surgical teams
 - the avoidance of futile surgery through informed discussion with the patient and family.
- The patient should be discharged to the ward with comprehensive orders.
- Preventative measures should be implemented for reducing complications.
- Instructions must be given in regard to further management when the patient is discharged from a clinical or surgical team.
- The potential outcomes from the probable clinical diagnosis must be considered when developing a treatment plan.
- The patient should be transferred to a medical unit if elderly and high-risk provided that the surgical postoperative care can be performed appropriately in that setting.

3. Improved protocol compliance

- All hospitals should have a formal protocol for early identification of clinical management issues and immediate management plans. This protocol needs to be updated according to national guidelines and policies.
- Hospitals should follow protocols. Failure to follow hospital protocol or national clinical guidelines during all parts of patient care can contribute to errors.

4. Action on evidence of clinical deterioration

- Clinical deterioration should be monitored. This is an issue that is recognised throughout Australia and internationally.
- When clinical deterioration occurs and no clear cause is identified, consideration should be given to causes outside the treating surgeon's specialty or expertise.
- Clinical findings must be considered alongside the results of investigations.
- Clinical deterioration must be acted on as well as recorded.

5. Improved awareness of surgical emergencies and sharing of care

- The audit revealed that patients admitted as surgical emergencies are at greater risk where care is shared. All health professionals should increase their awareness of this risk to improve the quality and safety of patient care.

6. Infection control

- The audit revealed that patients admitted as surgical are at an increased risk of developing infection. The Australian Guidelines for the Prevention and Control of Infection in Healthcare are designed to prevent and manage healthcare associated infection (HAI), these should be utilised at hospitals and VASM endorses their use to reduce the incidence of infection.
- Key actions to be taken for control and management are:
 - timely recognition
 - appropriate investigation
 - rapid administration of treatment
 - timely involvement of expert teams.

7. In-hospital fall prevention

- The audit revealed that patients admitted as surgical emergencies have a greater risk of falling while in hospital. All health professionals should increase their awareness of this risk to improve the quality and safety of patient care.
- The best practice guidelines for Australian hospitals, residential aged care facilities and community care are designed to facilitate practices that reduce falls and associated harm. The VASM endorses the use of current hospital protocols and guidelines to reduce the incidence of in-hospital falls.

8. Improved communication

- All health professionals and institutions should actively collaborate and communicate to effectively support an appropriate interchange of information and coordination of patient care at all stages during the admission episode.

Cardiothoracic Surgery

Case 1: Delay in diagnosis of ischaemic bowel after cardiothoracic surgery; communication issues

Clinical details:

A 78-year-old patient was admitted for elective replacement of the ascending aorta and aortic valve. The patient originally presented to the local doctor with an “arrhythmia” and a cardiac murmur was also noted. Investigations, including echocardiography and cardiac catheterisation, confirmed the presence of a 5.5 cm ascending aortic aneurysm with moderate aortic regurgitation, minor coronary artery disease and normal left ventricular contractility. A preoperative electrocardiogram (ECG) and Holter monitor both confirmed sinus rhythm.

At operation, the aortic valve was replaced with a 23 mm Magna Ease pericardial bioprosthesis and the ascending aorta was replaced with a 30 mm Dacron graft. The patient was transferred to the intensive care unit (ICU) on low dose adrenaline and noradrenaline infusions that were maintained for a short time. The postoperative rhythm was either sinus or atrial pacing and progress was satisfactory to the extent that the patient was transferred out of ICU to the high dependency unit (HDU) on day one postoperation. The patient’s status deteriorated over the subsequent 48 hours, with increasing renal impairment and complaints of abdominal pain with observed distention. The patient became oliguric and, during placement of an indwelling catheter, vomited, aspirated and sustained an asystolic cardiac arrest. The patient was resuscitated and transferred intubated and ventilated back to the ICU, where they were assessed as being in extremis with evidence of liver and renal impairment as well as severe metabolic acidosis and a marked rise in lactate level. A provisional diagnosis of ischaemic bowel was made and a general surgeon’s opinion was sought. The patient was considered very high risk and was not stable enough to undergo any further investigations. A decision was made for palliative treatment. The patient died on postoperative day five.

Assessor’s comments:

The surgical case form (SCF) completed by the consultant lacked the appropriate level of detail for several questions. In response to question three the main surgical diagnosis was given as ascending aortic aneurysm, with no mention of significant aortic regurgitation. The response to question nine, which relates to the course to death, comprised three lines describing the procedure as an elective replacement of the ascending aorta – there was no mention of the aortic valve replacement. It contained no details about the actual operation performed and no information about the patient’s progress prior to the development of the “presumed abdominal vascular catastrophe” on postoperative day four. As outlined by the first-line assessor, there was nowhere near enough information to enable any conclusions to be drawn.

The notes were deficient in their description of the preoperative status of the patient. While it was stated that the original presentation was with an “arrhythmia” there was no specific diagnosis made. An ECG and Holter monitor test performed sometime prior to the hospital admission demonstrated sinus rhythm. The admission ECG was not included in

the hospital notes. The notes were further deficient in that there was no operation report by the operating surgeon. The only report in the notes was a brief handwritten outline of the surgery, presumably by the surgical assistant, that described replacement of the ascending aorta and the aortic valve.

The operation performed on this patient was described in different parts of the hospital records as three different procedures. The surgeon's description in the SCF was replacement of the ascending aorta, while the assistant's description was replacement of the ascending aorta and aortic valve. Another note in the ICU stated that a Bentall procedure was carried out. This speaks of a significant lack of communication between the various members of the team looking after the patient.

Although the SCF claims that the patient progressed well until the sudden onset of a "catastrophe", perusal of the progress notes suggest otherwise. The nursing notes make mention of abdominal pain from as early as the afternoon of postoperative day one and this appears to have gradually increased over the ensuing 48 hours. By the evening of postoperative day three the abdomen was noted to be tender and distended. This persisted into the early hours of postoperative day five, by which time the patient was in established renal failure (progressive elevation of urea and creatinine from day two onwards). Following insertion of an indwelling catheter the patient vomited, aspirated and then arrested. It was only after resuscitation that the possibility of ischaemic bowel was mentioned, by which time the patient was in extremis and was not deemed a surgical candidate by the general surgery team.

The patient's notes contained a copy of a handwritten letter from a family member to the coroner stating that the family was aware that the patient was in severe abdominal pain by postoperative day three and had a distended abdomen the following day. Their expressed concern does not seem to have resulted in any recognition or action by the surgical team.

The main area of concern in this case is the failure to recognise an acute abdominal emergency that was almost certainly due to ischaemic bowel. Although the patient developed atrial fibrillation (AF) about day four, the ischaemic bowel symptoms preceded this and may have been due to other causes such as aortic cross clamping. Unfortunately the absence of a detailed operation report makes this speculation only, but the histopathology report does describe multiple intimal plaques. Alternatively, any period of significant hypotension could equally have contributed to this problem.

The other area of concern, which became apparent from the hospital notes, is that there was no obvious continuity of assessment during ward rounds by medical staff. One would have expected an earlier response given that the patient had daily observation and made daily complaints of abdominal pain. The fact that this deterioration occurred mainly over the weekend would simply serve to magnify this problem if covering staff were performing the ward rounds. The other feature of the medical records is that there were virtually no written notes by the surgical team doing the daily ward rounds. Most of the notes were written by the nursing staff.

Surgical lessons:

Earlier diagnosis of the ischaemic bowel complication may not have changed the ultimate outcome. However, since the patient was too unwell to undergo investigations or surgery by the time of diagnosis, no such conclusion can be drawn.

The standard of record keeping in this case was inadequate and this situation should be reviewed by the surgical unit and by the hospital. The continuity of management during surgical ward rounds should also be reviewed, particularly when night time or weekend cover is provided by staff who are not current members of the surgical unit.

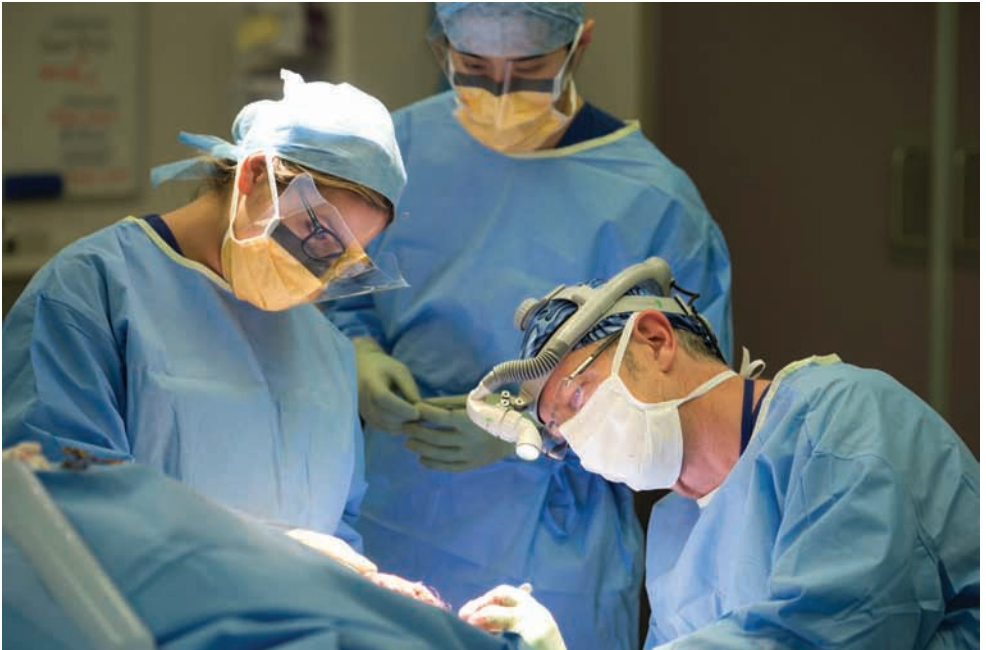It is imperative to keep accurate medical records. This case highlights a lack of meaningful notes from the surgeon - including the details of the operation, which is obviously a crucial piece of information in any patient admission.

The diagnosis of intestinal ischaemia after cardiac surgery is challenging. It carries with it a high mortality risk as recognition is often delayed.

Further reading; see Lorusso et al.⁽¹⁾

Reference

1. Lorusso R, Mariscalco G, Vizzardi E, Bonadei I, Renzulli A, Gelsomino S. Acute bowel ischemia after heart operations. *Ann Thorac Surg*. 2014 Jun;97(6):2219-27.



Cardiothoracic Surgery

Case 2: Redo aortic valve replacement with postoperative haemorrhage; delay in return to operating room

Clinical details:

This case is that of a redo sternotomy for aortic valve replacement in a high risk 85-year-old patient who had previously undergone quintuple coronary artery bypass grafting. It seems that the graft(s) to two circumflex marginal coronary arteries were occluded but the remaining ones, including the left internal thoracic artery to the left anterior descending coronary artery, were patent. Left ventricular function was good on transthoracic echocardiography, which also demonstrated calcific aortic stenosis and left ventricular hypertrophy. It appears pulmonary hypertension was recognised preoperatively. The patient was a high-risk case on the basis of morbid obesity (125 kg), advanced years, chronic renal failure, peripheral vascular disease (femoral artery atheroma; previous abdominal aortic aneurysm graft), chronic obstructive pulmonary disease (COPD), former smoker (ceased 18 years), pulmonary hypertension, diabetes mellitus, hypertension, AF, impaired mobility (four wheel frame) and previous coronary artery bypass graft (some grafts patent) requiring redo sternotomy and division of adhesions.

There was difficulty in weaning from bypass, with persistent pulmonary hypertension and resultant right heart dysfunction. Transesophageal echocardiography also showed impaired left ventricular function that appeared to improve with inotropes and filling. The patient was haemodynamically unstable and the surgeon was notified on two occasions after tamponade had been excluded on ultrasound. Persistent bleeding required a return to theatre the next morning but the patient arrested on the table and died.

Assessor's comments:

In view of potential surgical risks, other alternatives such as transcatheter or transapical valve implantation were probably contemplated. However, transcatheter insertion may have been precluded by peripheral vascular disease and the presence of the abdominal aortic graft or stent. In this particular case, presumably because of the existing risk factors, grafting to the circumflex marginal coronary arteries was not done. Because of the unavailability of the full operation report, it is not known whether this decision was made preoperatively for the sake of expediency or intraoperatively due to poor target vessels or difficult exposure. In any case, myocardial ischaemia does not seem to have been a problem in the patient's symptomatology and not grafting these two vessels probably had no material effect on the patient's subsequent course.

Absence of detailed operation notes makes assessment of any intraoperative difficulties encountered difficult to ascertain. For example, the question of whether the cardioplegia was adequate is difficult to answer. There was no information to indicate the type of cardioplegia used, the route of administration or how often was it employed. Other questions include:

- Were saphenous vein grafts disturbed during division of adhesions; was there distal coronary atheroembolism?
- Was bleeding prominent intraoperatively and was haemostasis problematic (Plavix appears to have been ceased only 4 days prior to surgery).

- Were there any technical difficulties in valve implantation; were the coronary ostia compromised?
- Were the proximal anastomoses of the saphenous vein grafts to the aorta compromised (the myocardium was totally dependent on graft flow as the native vessels were all obstructed)?
- Was the patent left internal thoracic artery (which would have required clamping during cardioplegic cardiac arrest) damaged?

The notes indicated that the patient was haemodynamically unstable immediately following the operation and remained so during what was reported as a “difficult” transfer to ICU. At this stage the patient was on three different inotropes (adrenaline, noradrenaline and Milrinone). According to the notes, the surgeon was critical of the setting up and administration of nitric oxide in the operating theatre (inadequate equipment and expertise). However, nitric oxide by inhalation was instituted in the ICU within 2 hours of return from theatre and cardiac output initially improved. The notes indicated that the drains were initially obstructed (kinked) and that significant drainage occurred once the obstruction was released. Thereafter, it appears the main problem was persisting high-volume haemorrhage requiring multiple transfusions of red blood cells (at least 24 units) and coagulation factors. Hypothermia was also a problem, not surprising given the large amount of transfusion being administered, and may have contributed to coagulopathy.

At this stage the patient was described as hypotensive and “vasoplegic” and vasopressin was commenced. Propofol was ceased (potential hypotensive agent) and morphine/Midazolam was commenced. However, the ongoing high-volume blood loss that persisted despite correction of hypothermia and coagulopathy. Tamponade was excluded on transoesophageal echocardiography. The surgeon was contacted about the blood loss on the evening of surgery and again in the early hours of the morning. Despite this it seems that correction of coagulopathy was persisted with until the patient was finally (at approximately 7:00 am) returned to theatre emergently on massive doses of inotropes and on the verge of cardiovascular collapse. The operation note (and at 10 words this was brief, to say the least) claims “no site found” but this was hardly surprising as at that stage the patient had arrested and was undergoing external then internal cardiac compression.

The question of the appropriateness of accepting this high-risk patient for surgical aortic valve replacement is a difficult one, and it is likely that the decision was not taken lightly. As indicated above, alternative procedures may not have been available due to factors such as peripheral vascular disease and the presence of an abdominal aortic graft. Redo patients are often elderly and despite the high risk the results are generally excellent. There are published Australian series with extremely low mortality rates, so the decision to accept a high-risk patient is ultimately a judgement call made by the surgeon and related specialities.

In this case, notwithstanding the other complicating factors of postoperative cardiac dysfunction and persisting pulmonary hypertension, it seems that an early return to theatre for exploration for bleeding may have led to a different outcome. It does sometimes occur that the ICU does not contact the surgeon regarding excessive loss in a timely fashion, but in this case it appears that bleeding was present from the beginning and that the surgeon was aware and was notified on at least one occasion prior to the last. It was not recorded whether the surgeon attended postoperatively to personally assess the patient, but after the call in

the early hours of the morning it is likely that this would have been appropriate. By 6:00 am the patient was in pre-arrest and could not be salvaged. Death occurred due to myocardial failure of indeterminate cause, but was significantly contributed to by massive transfusion for severe postoperative bleeding. The initial unavailability of nitric oxide in the theatre was probably not a factor in the outcome.

This death may have been preventable had a more prompt return to theatre occurred for surgical exploration. Of course, in a high risk elderly patient (pulmonary hypertension, parlous postoperative cardiac function, on massive inotropic support and with a coagulopathy) the risks of a return to theatre need to be weighed against the possibility that the bleeding could be nonsurgical. However, it is most unlikely that the massive postoperative blood loss was due to “medical bleeding” as claimed on the case report form. On balance and on the available evidence, an early return to theatre was the appropriate course.

The administration of Novo Seven was considered as it appears bleeding persisted despite attempted correction of coagulopathy. Early administration should have been tried given that the patient was being treated on the initial assumption that the bleeding was nonsurgical. As it turned out the patient was being taken back to theatre by the time that decision was being contemplated. The role played by clopidogrel (Plavix), a potent antiplatelet agent, in the haemorrhage in this case is undetermined. One needs to acknowledge the individual variability of response to clopidogrel, but in an elective redo case it would seem prudent to stop the medication at least 1 week prior to surgery.

Surgical lessons:

A lack of well-written operation notes is a feature of this case. While this may not have made a difference to the outcome, it is easier to understand the patient’s course when the initial stages are clear (e.g. clear statement of the operation performed the level of difficulty and whether there was any deviation from the norm).

Delays in return to theatre for bleeding after cardiac surgery are associated with worse outcomes, especially in high-risk cases such as this. Massive blood and factor transfusion with ongoing instability should indicate to the surgeon that a re-sternotomy ought to be strongly considered.

Topical haemostatic agents may be useful in redo surgery where there is a large raw surface area of “non-surgical” bleeding. There are many in the market to choose from. For a good review article see Barnard and Millner (2009).⁽²⁾

Reference

2. Barnard J, Millner R. A review of topical haemostatic agents for use in cardiac surgery. *Ann Thorac Surg.* 2009;88(4):1377-83.

General Surgery

Case 3: Pancreatic malignancy with biliary and duodenal obstruction; communication issues

Clinical details:

This case is that of a 67-year-old patient who presented to the emergency department (ED) of Hospital A with a 3-day history of abdominal pain and dark urine. A computed tomography (CT) scan ordered by his general practitioner had shown an irregular mass in the region of his pancreatic head, with obstruction of the biliary system and narrowing of the third part of the duodenum. The proximal duodenum was dilated and there were enlarged lymph nodes in the vicinity of the coeliac axis which were thought to be pathological in nature. The patient had undergone a curative subtotal gastrectomy with Roux-en-Y anastomosis 3 years earlier for a poorly differentiated adenocarcinoma. Chemotherapy was given after surgery, with the last follow-up a year prior to this admission.

Having been diagnosed with obstructive jaundice due to a carcinoma of the pancreas, the patient was transferred to a tertiary hospital in the same health facility as Hospital B under the care of the gastroenterology unit. By this time the patient was septic and unwell and transferred to ICU.

An endoscopic retrograde cholangiography cholangiopancreatography (ERCP) was attempted the day after admission, and although the biliopancreatic ampulla was cannulated successfully, the bile duct could not be reached. The biliary tree was then decompressed via a percutaneous transhepatic cholangiography. A period of clinical improvement followed briefly with his bilirubin falling. The patient's sepsis did not completely settle and his condition deteriorated, requiring circulatory support. A further CT scan a week later showed a large collection in the right upper quadrant. Two days later 600 mL of haemopurulent fluid was aspirated. While the initial gram stain was negative, subsequent culture showed Vancomycin-resistant *Enterococcus faecium*.

The day after the CT scan the patient further deteriorated with septic shock associated with a tender distended abdomen. The patient was seen by a surgeon who diagnosed peritonitis and organised an immediate laparotomy. The surgeon warned family members of a poor prognosis. Bile stained free fluid was found in all quadrants, with an infected haematoma in the right upper quadrant associated with a blown duodenal stump. The transverse colon was dusky, with a hard mass at the base of the mesocolon. A biopsy was taken, the perforation closed and a wash-out performed. The patient worsened rapidly and the procedure was terminated. Following a family meeting the patient was treated palliatively and died the next day. The intraoperative biopsy showed metastatic carcinoma.

Assessor's comments:

The first-line assessor was concerned that the patient was not referred to a surgeon on day one, rather than on day 10 when in a pre-terminal state. The second-line assessor agreed with the view of the first-line assessor and felt it was an act of discourtesy that the surgeon who performed the gastrectomy, and who it appears worked at the same hospital, was not informed of the patient's condition.

The case notes on the whole were satisfactory, except for the glaring absence of an ERCP report. There was no explanation of why the bile duct could not be accessed, and one wonders if the duodenoscope was not able to negotiate the third part of the duodenum, strictured by metastatic carcinoma. The surgeon who performed the gastrectomy would have been aware of the anatomy of the Roux-en-Y reconstruction and the feasibility of performing an ERCP. In retrospect, the duodenal stump blow-out was due to the introduction of air into the proximal duodenal loop, already obstructed by the malignant stricture of the third part of the duodenum.

On admission the patient was consented for both an ERCP and duodenal stent, but there was no evidence of an attempt to insert a stent. Surgical consultation at that time would have been helpful in discussing other management options. Palliative surgical bypass of both duodenum and bile duct could have been considered at an earlier time in a fitter patient.

By the time surgeons were involved the patient was pre-terminal and could not have been saved. The dusky transverse colon was most likely due to malignant involvement of vessels at the base of the mesocolon, and resectability is doubtful.

The earlier involvement of surgeons would have led to a discussion as to whether the tumour was a primary of the pancreas or metastatic gastric carcinoma. If it was the latter, the patient should have been admitted under the surgical unit.

Surgical lessons:

The appropriate management of malignant biliary obstruction is dependent on a number of factors relating to the pathology of the obstruction, the anatomical site of the blockage, impending involvement of adjacent structures, the availability and suitability of operative or nonoperative techniques and physical assessment and desires of the patient. Early surgical involvement is imperative in expediting the optimal treatment plan.⁽³⁾

Reference

3. Pu L, Singh R, Loong C, de Moura E. Malignant Biliary Obstruction: Evidence for Best Practice. *Gastroenterol Res Pract* [serial on the Internet]. 2016 11 May 2016]: Available from: <http://www.hindawi.com/journals/grp/2016/3296801/>.

General Surgery - Bariatric

Case 4: Gastric bypass with sepsis; nocturnal CT scan with aspiration in a patient requiring re-exploration instead of x-ray

Clinical details:

This 56-year-old patient underwent gastric bypass surgery on the background of a complex surgical past history. He had undergone gastric stapling, and then reversal of stapling, and multiple laparotomies for strangulated incisional hernia repairs with small bowel resection. The medical past history included osteoarthritis, hypertension, hypothyroidism, reflux and morbid obesity with a body mass index (BMI) of 47 on admission. The patient had a long history of trying to lose weight, having undergone his first surgery in 1980 while in his early twenties.

He underwent a gastric bypass after division of adhesions, was returned to ICU and was treated with inotrope support for hypotension. On the afternoon/evening of the third post-operative day the patient complained of back pain associated with worsening tachycardia, tachypnoea and acidosis that is usually indicative of an anastomotic leak. At this time it was also noted that the patient had started draining purulent fluid from the intra-abdominal drain tubes and had developed nausea with bilious vomiting.

During the postoperative period in ICU the patient initially required blood pressure (BP) support for 2 days with noradrenaline after which the patient became baseline tachycardic and tachypnoeic. A cardiac echocardiogram on day two had ruled out a pericardial effusion. The patient was submitted for a CT scan overnight prior to re-exploration but while in the CT scanner the patient aspirated and could not be resuscitated.

Assessor's comments:

On review of the case notes it was not unreasonable to perform bariatric surgery on this patient. The medical notes provided enabled the sequence of events to be determined although there were no notes from the surgical team.

Surgery in this patient was not without a high level of risk; however, of concern is the choice of operation for this particular patient. A gastric sleeve should have been performed instead. Patients with previous multiple laparotomies tend to have inherent non-clinical distal bowel obstruction which can predispose them to an anastomotic leak. Typically it is patients with insulin-dependent diabetes who are offered gastric bypass.

The notes state that there was a plan to perform a CT the following day (day four) or sooner, with probable return to theatre for an exploratory laparotomy because of the patient's ongoing deterioration. The decision to take the septic deteriorating patient to CT scan room overnight instead of performing emergency laparotomy is questionable. CT in these cases is not very diagnostic. As the notes read, the surgeon could have been notified earlier of the patient's deterioration and perhaps a decision to take the patient back to theatre may have been made earlier.

Of concern was the decision to transfer an acutely ill and rapidly deteriorating patient to CT in the early hours of the morning. While undergoing CT the patient's airway was unprotected, causing the patient to aspirate. Earlier surgical intervention without CT was warranted in this situation.

Treating surgeon's response to second-line assessment

I would like to briefly address a few issues in response to the second-line assessment I received regarding this patient.

The first matter is the decision to perform gastric bypass. A note in the assessment is that the reviewer would have been reluctant to perform gastric bypass and would have opted for gastric sleeve. In my opinion, it is an unacceptable risk to perform a gastric sleeve on a patient who has had previous gastric stapling. The problem with performing sleeve gastrectomy is that you have multiple staple lines and there is a significant risk of these staple lines intersecting during a sleeve gastrectomy, causing issues with ischaemic segments of stomach. This predisposes the patient to leakage from the staple line. Sleeve gastrectomy leakage is a significant problem as the high pressure of a sleeve means that the leaks rarely heal appropriately. This tends to result in a prolonged hospital admission and often mortality.

The reason that this patient had gastric bypass surgery was because of the previous gastric stapling, but also because of significant oesophageal dilatation above the area of stapling. It is my experience that you do not offer only Roux-en-Y gastric bypass to diabetics. Of course all bariatric surgeries are subject to controversy, and choice of bariatric operation is often dependent on the skill of the surgeon and the experience of the surgeon in regard to the particular procedure offered.

In regard to the remainder of the assessment, I agree that earlier notification of this patient's deterioration would have resulted in return to the operating theatre, rather than a CT in the middle of the night. I think it is a significant issue that this patient was moved with an unprotected airway from the ICU to a CT scanning table - morbidly obese patients with any evidence of peritonitis who are laid flat are liable to aspirate. It is my experience that these patients are much better off intubated in the operating theatre with laparotomy performed as soon as possible.

Thank you for allowing me to respond to the second-line assessment. I largely agree with the assessor's statements.

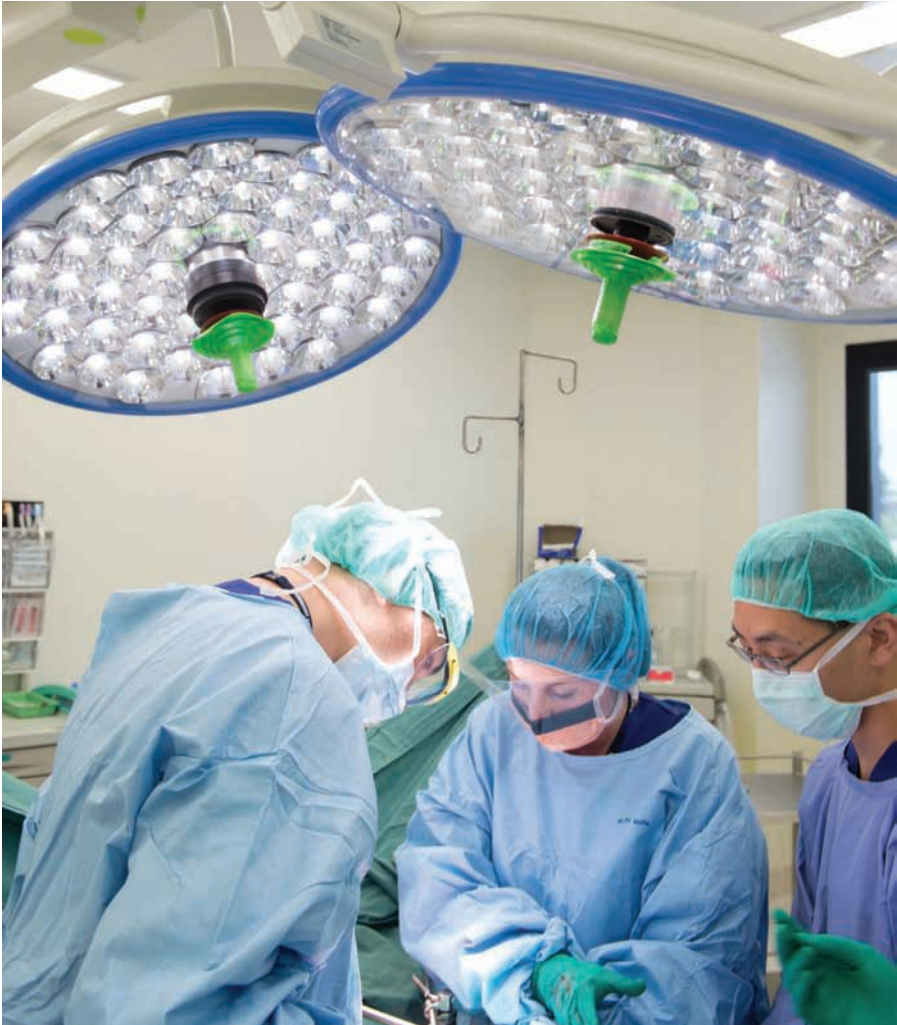Surgical lessons:

The most appropriate surgical intervention for the management of morbid obesity is still under consideration and is influenced by prior surgical procedures such as gastric stapling.⁽⁴⁾

Anastomotic leak is one of the most dangerous complications in gastric bypass surgery, and is associated with significantly longer inpatient treatment, long-term morbidity and higher mortality. Early postoperative intervention is crucial to achieve better results and avoid mortality. Early clinical indicators including tachycardia, hypotension, leucocytosis and positive fluid balance are more sensitive indicators of anastomotic leak than radiological tests, and mandate early surgical review.⁽⁵⁾

Reference

4. Clough A, Hamill D, Jackson S, Remilton M, Eyre R, Callahan R. Outcome of three common bariatric procedures in the public sector. *ANZ J Surg.* 2016 Apr 12.
5. Arteaga-Gonzalez I, Martin-Malagon A, Martin-Perez J, Carrillo-Pallares A. Usefulness of Clinical Signs and Diagnostic Tests for Suspected Leaks in Bariatric Surgery. *Obes Surg.* 2015 Sep;25(9):1680-4.



General Surgery

Case 5: Misdiagnosed postoperative complications after hemicolectomy

Clinical details:

This 84-year-old patient had a number of comorbidities including type 2 diabetes, morbid obesity (height 175 cm, weight 122 kg, BMI 40), hypercholesterolaemia, hypertension, mild asthma and anaemia (preoperative haemoglobin [Hb] concentration 87 g/dL). The patient presented with iron deficiency anaemia and positive faecal occult blood. A tumour was diagnosed at colonoscopy (right colon cancer [3 cm] and tubular villous adenoma [8 cm]) and a laparoscopic right hemicolectomy was performed.

The surgery was uncomplicated and the patient was monitored in the ICU following the procedure. An epidural had been placed along with an indwelling urinary catheter. On the third postoperative day there was concern with persistent tachycardia and hypotension and a CT scan was performed to exclude anastomotic leak. Left lower lobe pneumonia was diagnosed at this time but the CT copy was not in the attached file. Broad spectrum antibiotics were commenced. By this time 2 units of blood had been transfused and renal function had begun to deteriorate.

On day four a Code Blue was called at 7:19 pm and cardiopulmonary resuscitation (CPR) commenced. The impression was likely vasovagal episode however rapid sequence induction intubation was made requiring three attempts. A vascath was inserted to commence haemofiltration. Vasopressors were required for BP and pulse control.

Intravenous (IV) heparin was commenced because of a presumed pulmonary embolus (PE). Around this time the epidural was removed. By day seven postoperative a total of 4 units had been transfused and nasogastric enteral feeding had been commenced. A CT pulmonary angiogram was performed with the "suggestion of thromboembolism in the segmental branches of the right middle lobe" and "patchy consolidation of the right middle and both lower lobes".

By day eight a total of 6 units of blood had been transfused, maintaining an Hb of between 8 and 10 g/dL. On day nine the patient was extubated. Hypotension was again noted requiring vasopressors with a tachycardia and the patient was on dialysis through a haemofiltration catheter. On day 11 broad spectrum antibiotics were ceased and a permcath inserted.

On day 14 persistent hypotension was noted, vasopressors restarted and the clinical picture was considered to be due to sepsis. In consultation with the family treatment was withdrawn, and the patient died in the presence of family. An autopsy was refused.

Assessor's comments:

The hospital case notes provided were extensive but somewhat patchy. There was no record of the original CT scan, at which time the pneumonia was diagnosed and an anastomotic leak excluded. Dates were often missing, so it was hard to determine exact transfusion events. The handwritten postoperative orders were neither dated nor signed, and instructions on surgical care deep venous thrombosis (DVT) prophylaxis were absent (although these were recorded in the typed surgeon's notes).

Areas of concern:

Postoperative care: This patient had persistent hypotension requiring vasopressors, and worsening renal failure requiring haemofiltration and dialysis. It was not clear from the notes whether the postoperative bleed was entertained as a cause of the patient's hypotension and cardiac arrest event. This is despite the aforementioned hypotension with its sequelae and 6-unit transfusion over 3 days. The operation note mentions a bleeding pedicle which was controlled, and haemostasis was secured at the closing of the operation. However, it is of concern that bleeding was not entertained as a cause of the aforementioned.

DVT prophylaxis: While the typed operation note mentions Clexane the handwritten anaesthetic chart and the postoperative drug charts make no mention of this. The earliest entry of enoxaparin was on postoperative day three. A heparin infusion was commenced from day seven after the diagnosis of pulmonary embolism was postulated.

Diagnosis of sepsis: This was assumed to be coming from the chest on the basis of the CT and related to possible aspiration during the intubation process on day four. Negative blood cultures and sputum cultures are noted. While the CT on day three failed to show a leak at the time of tachycardia and hypotension, an abdominal source for sepsis does not seem to have been entertained. This may well have been less likely as time progressed and nasoenteral feeding was commenced.

Site suitability for operation: This was an issue raised by the surgeon. It seems from the notes that this patient was in a facility with ICU residents, registrars and intensive care consultants. While she had significant comorbidities, respiratory and renal support were clearly available and it is doubtful whether a higher care facility would have made any difference to the outcome.

Delay in CT pulmonary angiogram: The CT scan report on day seven was "suggestive of a thromboembolism" rather than a definitive diagnosis of major PE. Given that the heparin infusion had already commenced several days previously I am unconvinced that this delay made any difference to the outcome.

As mentioned above, a key concern is whether consideration was given to the possibility that an abdominal bleed may have been a primary cause of the deterioration. This is particularly important given that it does, in fact, seem likely. A resident entry on postoperative day seven questions bleeding with a "negative per rectum", but the question of intra-abdominal as opposed to gastrointestinal bleeding was not raised.

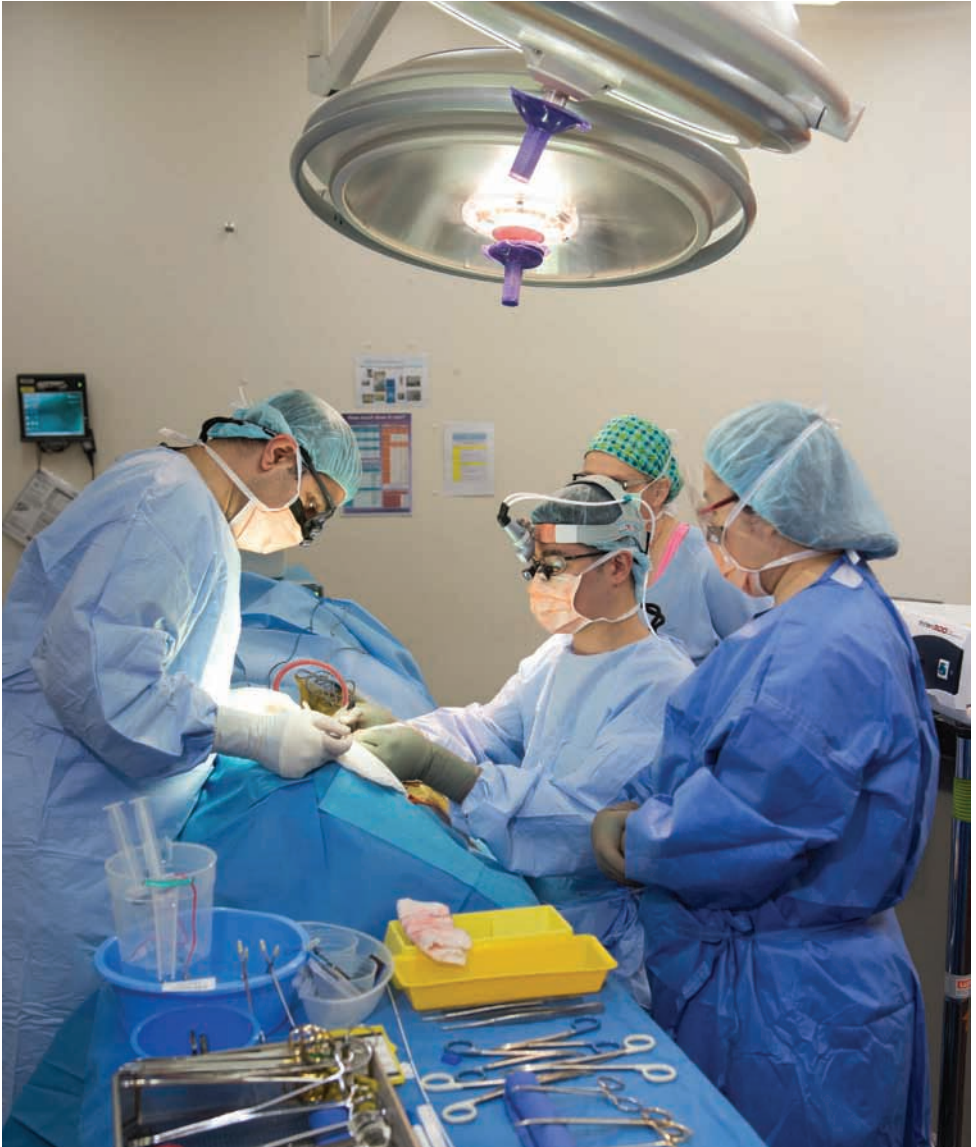Surgical lessons:

This operation was necessary for this patient, who had significant comorbidities, and the hospital facility was suitable. An abdominal source for the patient's hypotension was apparently not entertained, but rather it was put down to respiratory, sepsis and embolus.

A patient collapse after any abdominal procedure needs to have significant intra-abdominal pathology excluded (perforation, leak or bleed). It is unclear as to whether there is a true explanation of this patient's ultimate demise. While there were regular entry notes from the

general surgical ward round, it was not clear that the consultant surgeon had significant input into this patient's diagnosis and management, or that there was interaction with the ICU consultant. Entries by the ICU consultant were clear, but gave no indication of interaction with the surgical team.

This may be an area for further discussion.



General Surgery

Case 6: Colovesical fistula repair in a septic patient; when is a patient too ill for surgery?

Clinical details:

A patient who lived alone presented to the ED of a hospital by ambulance with 1 month urinary tract infection (UTI) symptoms where two courses of antibiotics were administered by the local medical officer. Reviewed four days previously for loose bowels and abdominal pain. Comorbidities included COPD and the patient was a smoker.

No vital signs were taken in triage despite ambulance observations (Systolic Blood Pressure (SBP) 90/Diastolic Blood Pressure (DBP) unrecorded, heart rate [HR] of 120 beats per minute (bpm), respiration rate of 24). The patient was subsequently transferred to a resuscitation cubicle. Initial blood results were Sodium (Na)/Potassium (K)/Urea/Creatinine (Cr) 130/4.1/22/357, Prothrombin time/International Normalised Ratio (INR)/ Activated Partial Thromboplastin Time 17.0/1.3/51, lactate 10.0.

A CT scan showed sigmoid diverticular disease with pericolic inflammatory stranding and pericolic collections (with air within bladder [indwelling catheter in situ]). IV antibiotics were administered over 1 hour: ceftriaxone 1 gm at 8:35 pm, metronidazole 500 mg at 9:10 pm and ampicillin 1 gm at 9:40 pm.

There was no indication as to what time the surgical team was notified. The ED notes at 9:24 pm state that the CT was reviewed by the surgical registrar (a hypotensive acute abdomen had been in the department for 2 hours). The surgical admission time was annotated at 9:00 pm but the name blanked with no designation or signature. It indicates “discussed with on-call consultant” and an initial plan for non-surgical management. This included triple antibiotic therapy and deep vein thrombosis (DVT) prophylaxis (an initial dose of Fragmin was given at 9:45 pm) despite the admission coagulation screen showing early coagulopathy. All further chemical prophylaxis was withheld.

The ICU admission/discharge notes showed that the patient was reviewed by a surgical registrar and discussed with a consultant. “Feel that the patient is too unstable for theatre and risks outweigh benefits given contained perforation rather than frank peritonitis.” Additional investigation included an ECG which indicated moderately severe global impairment left ventricular systolic function. The notes went on to explain that “if continues to require increasing inotropic/vasopressor support, to rediscuss with surgeon for source control tonight ” and “O₂ to maintain saturation at 92 per cent”.

By morning the patient was on noradrenaline, vasopressin and adrenaline. The desired O₂ saturation was never quite achieved despite increasing oxygen flow rates and delivery systems before eventual intubation and ventilation at 8:10 am. The patient was reviewed in ICU by the surgical registrar at 8:10 am and again discussed with the surgical consultant. A decision was now made for laparotomy. At surgery, a Hartmann’s procedure with suture repair of the vesical defect was performed. A drain was placed to the pelvic abscess.

Despite the appropriate surgical intervention the patient continued to deteriorate postoperatively. The decision was made to withdraw inotropic support and the patient died less than 24 hours after being returned to the ICU from theatre.

Assessor's comments:

It is current practice to prescribe gentamicin-based regimes as the treatment of choice for most intra-abdominal infections; however, the regimen prescribed for this patient did not conform to the guidelines. Gentamicin was substituted by ceftriaxone. Penicillin sensitivity was not an issue as the patient appears to have been given ampicillin. This is not the recommendation (i.e. piperacillin and tazobactam) for non-sensitive patients if an amino glycoside is contraindicated. A single dose of gentamicin is not reasonable in such a desperately ill patient. Almost an hour after the initial blood tests were performed and the renal impairment identified, the patient was given IV contrast for the CT scan (the eventual blood culture result - *Escherichia coli*, *Enterococcus faecium*, anaerobic gram positive bacilli, *staphylococcus aureus*- indicates a very extreme situation).

The decision not to operate at presentation is a judgement call. Surgery should not be undertaken before adequate resuscitation. The plan outlined in ICU was qualitative. No indication of the threshold to invoke surgical management was outlined and the patient continued to progressively deteriorate overnight with respect to their cardiovascular and respiratory status. The reassessment was left to the default position of "in the morning". There was a clear surgical pathology. Participants at the Care of the Critically Ill Surgical Patient course are strongly reminded of the need for surgical control at the earliest opportunity. One recalls a comment during general discussion of one of the cases presented at the VASM/ Victorian Managed Insurance Authority training essentials session: Surgical Emergencies and Shared Care Seminar held in February 2014: "(in emergency surgery) is a patient ever too sick to operate?"

There was no documentation provided "right colon cancer (3 cm) and tubular villous adenoma (8 cm)" by a senior clinician in attendance on admission when key decisions were made or more importantly, of direct communications between the senior clinicians managing this case. The admitting surgeon was involved in only two discussions with the surgical registrar.

No communication regarding transferring the patient's care was in the material provided. There was no indication of an independent assessment and decision by the operating surgeon. The operating surgeon considered the outcome not preventable and expected. This is surely a definition of futile surgery and the decision to proceed, perhaps, should be an area of consideration.

Neurosurgery

Case 7: Hydrocephalus with delay to treatment and in response to postoperative complications

Clinical details:

This is a case of a 54-year-old patient with known acquired brain injury secondary to meningitis complicated by hydrocephalus. The patient presented 3 weeks earlier to the ED with drowsiness, and according to the ED notes, was planned for admission under neurosurgery for magnetic resonance imaging (MRI). CT head showed dilated ventricles, but the changes were deemed by the neurosurgery team as chronic. The patient was discharged as clinically well and admitted under the medical unit with hyponatremia and a UTI.

The patient's hyponatremia and UTI seemed to be well treated but the patient remained very drowsy. MRI was performed and was reviewed at the medical unit radiology meeting, at which time the patient was found to have new acute transependymal oedema. The patient was also found to have a large retrosternal goitre, for which fine needle aspiration was unsuccessful.

The patient was seen by neurosurgery, discussions held with the family, and the patient was scheduled for surgery for the following week. The procedure was subsequently cancelled and rescheduled for the following week pending review by an otolaryngology head and neck surgeon for the goitre. An uneventful endoscopic third ventriculostomy was performed. The patient was managed in the medical unit postsurgery. There was improvement in the patient's conscious state however the patient developed vomiting on day seven postoperation and became drowsy again shortly after. CT head performed on day nine showed prepontine haemorrhage, and the patient was transferred to neurosurgery. The patient's condition remained poor and after discussion with the family the patient was palliated.

Assessor's comments:

The first line assessor's concerns were about; the sodium level prior to surgery, the UTI control prior to surgery, postoperative subarachnoid haemorrhage and ongoing hydrocephalus and the vessel injury during the third ventriculostomy. These were considered significant complications and are potentially preventable factors in the patient's death.

The operation notes suggest that there was no bleeding or vessel injury noted during the procedure. The patient also improved clinically after the procedure, which suggests that this was a delayed complication. It is possible that a small perforator vessel was injured during the procedure, but in the absence of observable bleeding during the procedure it is very difficult to detect.

It is likely that hydrocephalus was a significant contributor to the drowsiness, and the hyponatremia and UTI were minimally contributing. The patient had presented 3 weeks prior with similar symptoms. The emergency doctor noted that neurosurgery declined ward care. The patient was managed by the medical unit. The patient remained drowsy even after the hyponatremia and UTI were corrected, but no surgery was undertaken for more than a week.

The patient would have done better to have been admitted under the neurosurgery unit, and observed closely, with daily and frequent review and input by the medical unit. A formal fundoscopy by ophthalmology to check for papilloedema would have helped elucidate any raised intracranial pressure.

The MRI should have been performed immediately after admission, and this would have shown the acute new transependymal oedema. It was done almost a week after admission. Diversion of the cerebrospinal fluid should have been performed urgently rather than electively and there was delay of more than another week before the surgery. A ventriculoperitoneal shunt or external ventricular drain would have been a better and surer procedure given the patient's past history of meningitis, which suggests a communicating hydrocephalus. Endoscopic third ventriculostomy has a lower success rate than these procedures, and given the delay in the relief of the hydrocephalus, a procedure with a higher success rate should have been performed.

The endoscopic third ventriculostomy was uncomplicated. It would have been useful to leave an external ventricular drain in place for a few days after the procedure: to check for any bleeding, monitor the intracranial pressures, and serve as an emergency vent for the cerebrospinal fluid. The patient should have been observed and managed in the neurosurgery unit after the procedure. The patient was back with the medical unit after the surgery, with neurosurgery review infrequent after a few days.

Vomiting on the seventh postoperative day should have raised suspicion of raised intracranial pressure, or caused concern that bleeding may result from the valsalva. There was delay in obtaining the CT scan, even after the patient became drowsy, as well as a delay in obtaining a neurosurgical review.

Surgical lessons:

This case illustrates a complex situation in which multiple clinical conditions placed a cloud over the correct treatment. In a classic example of "not seeing the forest for the trees", the multiplicity of illnesses including electrolyte imbalance, UTI and the retrosternal goitre may have clouded the judgement of the initial neurosurgical team, leading them to believe that the hydrocephalus secondary to meningitis was of little to no clinical significance. This case illustrates how easy it is to compartmentalise conditions to a point where the most critical illness can be considered of no clinical significance. Both the first- and the second-line assessor identified the hydrocephalus as a major contributing factor to the decline of the patient. Had the clinically significant ventriculomegaly been recognised and managed, the subsequent issues with brain-stem haemorrhage, the need to operate upon a sick patient in an urgent manner and overall delays could have been avoided.

Neurosurgery

Case 8: High risk recurrent meningioma with intraoperative complications; is palliation the best option?

Clinical details:

This patient was elderly with a number of age-related comorbidities. The patient previously had surgery and radiotherapy for an aggressive right frontotemporal meningioma, which had recurred. Follow-up radiology revealed a “dramatic” increase in the size of the tumour (scan report not seen), but the patient remained in reasonable health apart from epilepsy. After due discussion further surgery was undertaken.

There were problems with vascular access in that the left carotid was injured initially and subsequently the right femoral artery was damaged while attempting to cannulate the femoral vein. At operation the tumour was found to be invading the brain and was very vascular. There was significant intraoperative bleeding and cortical damage due to the invasive nature of the tumour and associated pathological vessels. Postoperatively there was a dense left hemiplegia. Despite ICU care there was no improvement and the decision was made to palliate the patient after due discussion with the power of attorney.

Assessor’s comments:

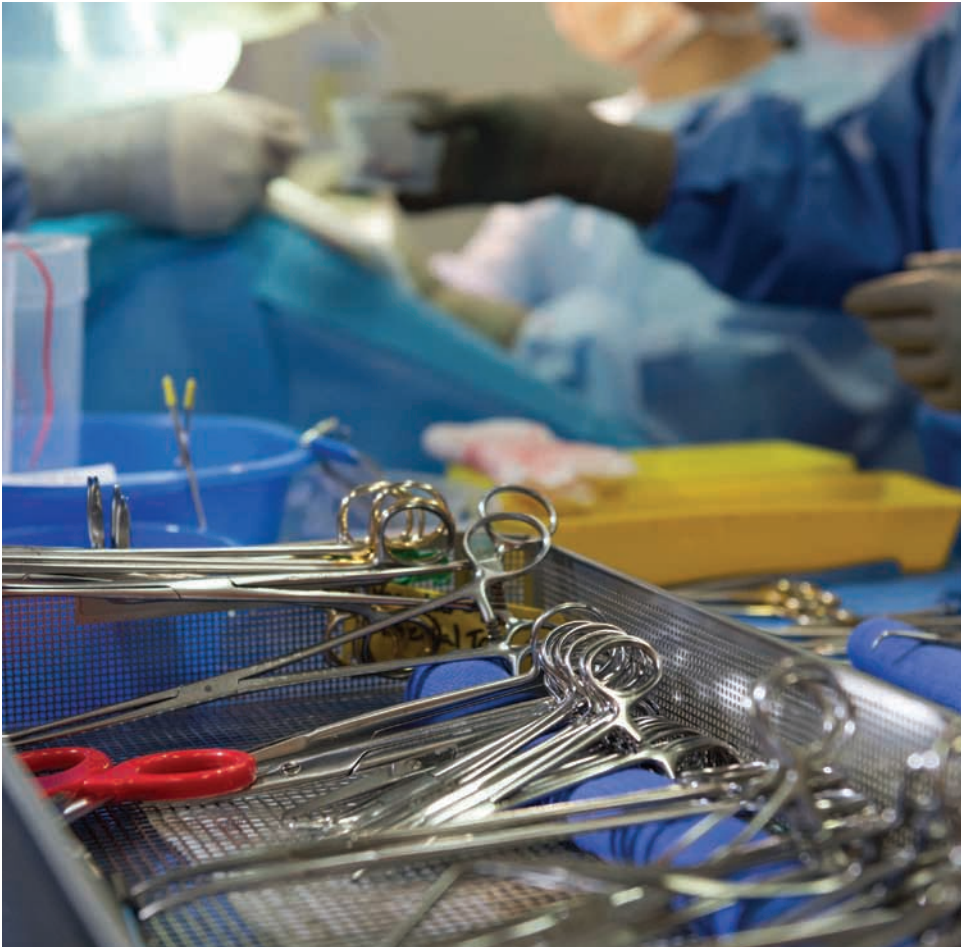With regard to the first-line assessor’s comments, there does not appear to have been a formal multidisciplinary meeting to determine treatment. However, in a private setting this is not always standard practice, and there does seem to have been discussion with the patient’s closest associates. It would seem that further radiotherapy or chemotherapy would have had no role in management of this tumour, and the options were either risky surgery or mere palliation.

The risks of surgery were very significant given the large malignant recurrent tumour with oedema and cortical invasion (which should have been seen on preoperative MRI), particularly in an elderly diabetic taking aspirin with previous radiotherapy. A preoperative angiogram would not have made much difference apart from alerting the surgeon to the pathological vasculature. Embolisation would also not have helped in my view. Clearly there was overall very significant intracranial blood loss and hypotension (boluses of Aramine given preoperatively), made worse by the further bleeding from the femoral artery. It is difficult to see how this could have been avoided and the option of partial removal or debulking would have been impractical. Once the craniotomy had commenced the conservative treatment option was not possible.

There are some concerns regarding the experience of the anaesthetic staff, given the difficulties with vascular access, but there can be issues with this in older patients. The anaesthetist commented correctly in the preoperative notes “very high risk anaesthetic.” Whether the operating surgeon was experienced in such high-risk surgery is unknown, but perhaps she or he could have given more weight to the possible intraoperative consequences, and emphasised to all the likelihood of complications. These difficult cases may benefit from the assistance, both preoperatively and intraoperatively, of a second experienced neurosurgeon.

Surgical lessons:

This case illustrates a complex and atypical meningioma in an elderly patient with extensive comorbidities. The struggles experienced by both the anaesthetic and the surgical staff were inherent and were well described. Several issues were raised in both the first- and second-line assessments, but the summation would be one of poor recognition of limitations by various staff members and the nature of the illness. Further, the limitation of the disease meant that direct surgical resection may have been better managed with a staging of the procedure. The realistic aims of managing this condition were also called into question as, in some instances, when the situation becomes difficult to manage, there are modalities to aid in withdrawal such that another approach or no approach at all can be reconsidered. This case does highlight a situation that should be considered in all cases where a straight-forward removal of a lesion is not always in the best interests of all involved.



Neurosurgery

Case 9: Cerebellar AV malformation treated with both embolisation and excision; in which order should these be performed to reduce brainstem compression?

Clinical details:

This case involves a 50-year-old patient who woke with a sudden severe headache, rapidly lost consciousness and became deeply comatose. CT angiogram (CTA) showed a large right cerebellar haematoma with underlying cerebellar arteriovenous malformation (AVM) causing brainstem compression and hydrocephalus.

Insertion of an external ventricular drain was performed, followed by cerebral angiogram and embolisation of the cerebellar vermian AVM. Complete obliteration was achieved. The patient was taken back to the operating theatre for posterior fossa craniotomy, evacuation of haematoma and excision of the obliterated AVM.

The patient remained deeply comatose. The postoperative course was complicated by multiple aspirations, cerebrospinal fluid leak from the craniotomy wound, desaturations and aspiration pneumonia. Eventually the patient was palliated after discussions with the ICU, neurosurgical team and family.

Assessor's comments:

The first-line assessor's comments were: "Why embolisation? Why not evacuation, did the delay in removing the haemorrhage and AVM contribute to death?"

This patient was admitted in a deeply comatose state from brainstem compression secondary to the cerebellar haematoma, and hydrocephalus. The patient's Glasgow Coma Scale (GCS) score was 3 but the pupils were reactive. No record was made of assessment of the other brainstem reflexes.

The decision at this point would either be to operate immediately, and deal with both contributors to the patient's poor neurological state, or palliate the patient.

Once the decision was made for surgical intervention, insertion of the external ventricular drain would deal with the hydrocephalus but would not relieve the brainstem compression. The patient's brainstem remained compressed for several hours (while the angiogram and embolisation were performed) before the second operation was performed. This might have contributed to the patient's mortality.

A better approach would have been to insert the external ventricular drain and perform a wide posterior fossa craniectomy at the same time. If necessary, part of the haematoma could have been evacuated if the cerebellum was still very swollen. This could have all been performed at the same first operation. Some haematoma should be left around the AVM, and the AVM should not be excised at this stage. This would have more effectively and rapidly reduced the brainstem compression.

The AVM should not have been excised at the first operation without an angiogram and possible embolisation to reduce the vascularity of the AVM. The AVM was not well visualised on the CTA; the cerebellum was swollen and haemorrhagic. Even in very experienced hands, attempting excision of the AVM under such circumstances would be very challenging. Any attempt to remove the AVM without a full and detailed study of its angioarchitecture might have resulted in uncontrolled bleeding and intraoperative mortality.

If complete obliteration of the AVM was achieved during the angiogram, a second operation would not be necessary if the brainstem was adequately decompressed from the first operation. Even if there was still residual AVM, a second operation could still be planned for a later stage when the cerebellar swelling had subsided and the patient showed signs of neurological improvement.

The re-haemorrhage rate from a ruptured AVM is known to be much lower than that for ruptured cerebral aneurysms (about 5%-10% in the first year), allowing for a more elective, controlled and prepared operation if necessary and indicated. It would have been reasonable to offer palliation to the patient's relatives given his poor GCS score of 3 (in deep coma), which would indicate a low likelihood of a good outcome with intervention.

The literature suggests that patients with a cerebellar haematoma admitted with a GCS score of less than 8 have high mortality rates and poor outcomes. However, once surgical intervention was decided, a more aggressive and decompressive operation would have given the patient the best possible chance for neurological recovery.

Surgical lessons:

This was a dire scenario in which an individual with a ruptured AVM and significant intracranial haemorrhage was already in a devastated state. The options were to palliate the patient or surgically deal with the haematoma and subsequently the AVM. Once an operative approach had been decided on, surgical decompression via evacuation of the haematoma would ideally proceed, with subsequent investigation and endovascular treatment considered once the stability of the patient had been secured.

Given the information provided it is likely that the outcome for this individual would have been devastating irrespective of the approach taken. However, as in surgical cases in other specialties, once a space occupying mass is exerting focal force upon vital structures, the first treatment is to consider removing such space occupying lesions. The definitive treatment for the AVM can then be considered either with endovascular support or in a staged manner.

Orthopaedic Surgery

Case 10: Palliative approach should be considered for a fractured neck of femur in a patient with terminal metastatic prostatic carcinoma.

Clinical details:

This case is of an elderly patient with right neck of femur (NOF) fracture (peritrochanteric) who underwent operative fixation the day after admission with long gamma nail and HydroSet bone graft.

The patient was in the terminal stage of prostate cancer with extensive bony metastases. He also had multiple comorbidities including AF, congestive cardiac failure, ischaemic heart disease and coronary artery grafts. Medications were warfarin, digoxin, Lasix, bisoprolol and Endone. The patient was not on any active anticancer treatment.

Prior to the incident the patient was living at home with his wife for palliative care and walked using a four wheel walker. The patient had an unwitnessed fall after getting out of bed and was transferred to hospital by ambulance with no loss of consciousness. The patient was admitted and reviewed by medical, orthopaedic and anaesthetic teams.

The reasoning for the operation was palliative to decrease pain, although the patient was not for resuscitation. The patient's initial INR was 2.5 but after 2 units of fresh frozen plasma (FFP) and vitamin K over 2 days had decreased to 1.6 on the day of the operation.

Under general anaesthesia, the operation started at 8:05 pm and finished by 8:45 pm. He was transferred to the ward 4 hours later. IV antibiotics and anticoagulant (40 mg Clexane daily) were commenced. Postoperatively the patient had some on/off confusion (GCS 9-10 to start and eventually GCS 14) but later ambulated to chair. Although oral intake was started, his urine output decreased on the third day and IV fluid was given. He had cold peripheries, his feet were oedematous and the issue of palliative treatment was discussed with the family.

While the patient was waiting for transfer to a nursing home his level of consciousness deteriorated. Respiratory Rate increased to 25-20 per minute and urine output was still nil overnight. Major deterioration occurred the morning of day four: the patient was not conscious and developed Cheyne-Stokes breathing. The issue of palliative treatment was again discussed with the family. Eventually respiration ceased with no heartbeat, dilated pupils unreactive to light and at 8:10 pm the patient passed away.

Assessor's comments:

Considering the multiple comorbidities on a background of bony metastatic of prostate cancer and NOF the choice of operation (gamma nail) is only justifiable as palliative care especially when the patient is not for resuscitation. However there are many surgeons who prefer not to perform this operation due to considerable/expected risk of death.

Overall, if we accept the idea of operating as a palliative care for above mentioned patient, the choice of operation, speed, preoperative evaluation, postoperative review and care were adequate and acceptable.

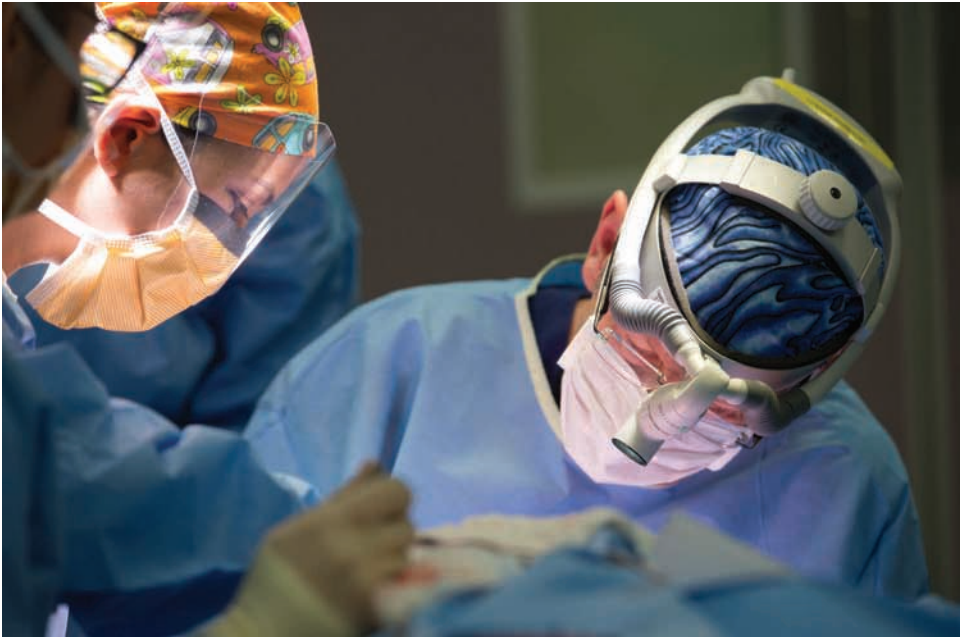Inaccurate (mismatch) documentation on the first VASM form and history regarding operation type – dynamic hip screw vs. Gamma Nail. Also the start time of operation was mentioned as 4:30 pm in an earlier report vs. 8:05 pm in the patient history.

The patient, with AF and taking warfarin (initial INR 2.5) who received two packs of FFP and vitamin K on 2 days prior to operation eventually with INR 1.6 when operation was done, was at a major risk of embolisation. The balance between therapeutic level of anticoagulation and bleeding risk remains a matter of clinical judgement by the treating team.

Operative versus nonoperative treatment for NOF patients with end stage disease is another unresolved and challenging problem for medical and surgical teams. A proper guideline, confirmed by senior surgical (orthopaedic) authorities, would be a very helpful tool to assist decision-making in future cases.

Surgical lessons:

Careful thought should be given to decisions about surgery in patients with extensive metastatic disease. Surgery is not indicated if the patient presents in a pre-morbid stage, but palliative surgery can be worthwhile in patients expected to survive for a prolonged period. However, it should be recognised that this is high-risk surgery, and the outcomes are not always those that are hoped for. In this case the surgeon probably made the correct decisions but the outcome was unsuccessful.



Orthopaedic/Anaesthetic

Case 11: Vascular and bony complications after anterior approach for elective total hip replacement; steep learning curve for new surgical approaches.

Orthopaedic review

Clinical details:

This 91-year-old patient was admitted to a private hospital for an elective total hip replacement. The patient had severe symptoms from the hip, and was assessed by a physician preoperatively. A general anaesthetic was used with an arterial line intraoperatively. An anterior approach was used with uncemented components, and a femur fracture was noted and required a cable. Blood loss of 1,000 mL was recorded intraoperatively and fluid replacement and inotropes were used for BP support.

Postoperatively he was transferred to ICU. A CTA suggested fracture of the acetabular floor and bleeding from a branch of the profunda femoris, but the patient was not stable for an exploration. Moderate coagulopathy was treated.

Over the next 36 hours, and despite volume and pharmacological support, the patient's BP mostly remained low and then urine output decreased as renal function deteriorated. The patient died about 48 hours after the end of operation.

Assessor's comments:

In general the records were complete and progress was well documented. The exceptions to this were that there was no documentation of the anaesthetic status on the anaesthetic record and no mention of the decision to not haemofiltrate. Neither the physician nor anaesthetist recorded that the patient was in AF preoperatively. The anaesthetic record shows only the systolic blood pressure (SBP) and pulse rate and no diastolic BP, and with no electronic printout. ICU records were comprehensive, although it was difficult to see when inotropes were given and at what dose.

The lack of important details in the operation report is of significant concern. The report fails to mention the significant blood loss – there was no mention of the site of the blood loss or whether any measures were undertaken to control it. The operation report describes a “defect” in the femur, but the SCF reports a fracture.

A fracture of the femoral shaft, an injury to a branch of the profunda femoris and a possible fracture of the acetabular floor occurred during what should have been a routine hip arthroplasty. Significant bleeding occurred, but if the surgeon made efforts to control this they are not documented. This was clearly an adverse event which significantly altered the clinical course of the patient, but this was not entered as an adverse event on the SCF.

In theatre the anaesthetist responded with fluid replacement and inotropes, and the patient's BP was satisfactory. After leaving the operating theatre there was a period of over 4 hours during which the patient's SBP was always below 110 mm Hg. There was nothing in the notes to suggest that the recovery nurse was communicating with the anaesthetist. In ICU, further resuscitation occurred with fluid, packed cells, clotting factors and inotropes. The SBP

improved in the mid-afternoon of the operative day, but diastolic and pulse remained low. ECG on postoperative day one showed complete heart block, but this was not recognised in any of the ICU progress notes.

The use of an anterior approach for this patient is debatable, and depends very much on the surgeon. There is a learning curve to this approach, and if this surgeon had performed this approach on a large number of patients with few complications then it would have been appropriate to use it on an elderly patient who was likely to have some osteoporosis. However, if the surgeon was not well experienced in this approach, then the femoral fracture could be partly attributed to this lack of experience. This may have been avoided if the surgeon had decided to use an approach with which they were more familiar.

There was nothing in the record to indicate whether the surgeon considered the use of cemented components. These can sometimes reduce blood loss from actively bleeding bone compared with uncemented components, but the cement can sometimes produce circulatory problems. The reduced need for a tight fit for the cemented femoral component may have reduced the likelihood of a fracture, but once one occurred it was reasonable to use an uncemented component.

Many surgeons do not use wound drains after joint replacement, but the use of reinfusion drains in this patient after 1000 mL of blood loss in theatre may have been helpful to control wound ooze and allow blood reinfusion. Tranexamic acid in theatre may have reduced bleeding.

Surgical lessons:

There were significant discrepancies between the SCF and the medical records. An adverse event occurred in theatre but the surgeon has not recognised this. The description of the operation in the SCF was inadequate, and the prolonged periods of profound postoperative circulatory failure are at odds with “haemodynamically he stabilised”. The patient’s renal failure and death were almost certainly related to his postoperative hypotension, and the SCF should show this but does not.

Appropriate management after significant blood loss in theatre and some further bleeding postoperatively are vital in maintaining perfusion to the brain, myocardium and kidneys, and assessment of the case history by an anaesthetist or intensivivist should be considered.

Questions should include:

- Should a Thallium-Persantin scan have been performed preoperatively?
- Postoperatively, was the patient in complete heart block, and would a temporary pacing wire have increased his cardiac output?
- Should coagulation studies have been performed in recovery?
- Was a mean arterial pressure (MAP) target of 70 mm Hg high enough in a patient of his age and echo findings?
- How much did the fact that it remained below this level for most of day one postoperatively contribute to his death?
- Were the records of inotrope support adequate?

Anaesthetic review

Clinical details:

A 91-year-old patient died 2 days after elective total hip replacement surgery. The procedure was complicated by an intraoperative femoral fracture. Postoperatively the patient was transferred from the recovery room to the ICU where the patient required management for hypotension and postoperative bleeding. Acute kidney injury developed and progressively worsened. The patient died approximately 48 hours postoperatively, after developing a bradycardia that was unresponsive to atropine and adrenaline.

The patient underwent an elective total hip replacement for advanced osteoarthritis. He suffered from osteoarthritis of the hips, knees and lumbar spine. His past history included right hip and knee replacement surgery, and hypertension. Cardiovascular medications included Karvezide (irbesartan/hydrochlorothiazide).

Preoperatively: Approximately 1 month preoperatively the patient underwent a medical review to assess his fitness for surgery. Exercise tolerance was noted to be limited by hip pain, with only short distances ambulated using a four wheel walker. The patient had no medical history of cardiovascular or neurovascular disease and had no previous thromboembolic events. BP was 140/80 mm Hg and HR 60 bpm. The patient was noted to be in sinus rhythm. His chest was clear on auscultation. Weight was recorded as 83 kg and BMI as 32.4.

An ECG was noted to show a right bundle branch block, Q waves in leads III and aVF, and first degree AV block. An echocardiogram performed four days later showed mild left ventricular hypertrophy with an ejection fraction within normal limits (56%). No regional wall motion abnormalities were identified.

No regional wall motion abnormalities were identified. The patient was in “controlled atrial fibrillation” at the time of the study. Preoperative blood test results included: Na⁺ 129 mmol/L, urea 7.7 mmol/L and Cr 117 umol/L (ref. range 60-110). Hb was 16.3 g/dL and platelet count 217x10⁹/L. Coagulation studies were within normal limits.

On the day of surgery: BP was 184/81, HR 57 and arterial oxygen saturation (SaO₂) 96%. Anaesthetic preoperative assessment described the patient’s general health as “stable”, with treated hypertension (noting the BP of 140/80 mm Hg at the time of preoperative medical assessment).

Intraoperatively: General anaesthesia was induced with propofol, cis-atracurium, and alfentanil. It was maintained with propofol. Fentanyl was administered towards the end of the case. The patient’s lowest recorded SBP was 100 mm Hg, with the majority of recorded SBPs > 120 mm Hg. Ephedrine (30 mg) was given approximately 30 minutes after induction, and metaraminol (dose unclear) was administered towards the end of the case. HR remained between 55 and 80 bpm, and the SaO₂ between 96%-99%. The hip replacement was performed via an anterior approach and took approximately 1.5 hours. The procedure was complicated by a proximal femoral fracture. An estimated blood loss of 1000 mL was documented on the anaesthetic record. At the end of the procedure an arterial line was inserted and the patient was transferred to the recovery room. Two 80 mcg doses of naloxone were administered before leaving the operating room.

In the recovery room: The patient arrived in the recovery room with a SBP of approximately 105 mm Hg, an HR in the 60s, and a SaO₂ of 100% on a Hudson mask. Within 15 minutes of arrival the patient had become hypotensive with a SBP in the 80s. The remainder of recorded BPs in the recovery room from this point ranged between approximately 80/42 mm Hg and 105/60 mm Hg, with an HR of 50-60 bpm in sinus rhythm. While in the recovery room the patient was given 250 mL of a hydroxylethyl starch (HES) solution. However, as the time of HES administration was not recorded it is unclear from the notes whether there was an improvement in BP in response to the fluid. No vasopressors were administered. Hb was 11.9 g/dL, reduced from 16.3 preoperatively. The patient was in the recovery room for just under an hour before being transferred to the ICU. There was no record of any discussions with, or review by, anaesthetic, surgical, or ICU staff in the recovery room notes. Total IV fluid administration recorded for the intraoperative and recovery room periods was 2750 mL of Compound Sodium Lactate (CSL) solution and 250 mL of HES solution.

Admission to ICU: At 12:30 pm on arrival in ICU the patient's BP was 82/33 mm Hg with a HR of 58 bpm, and SaO₂ of 100% on 5 L/min oxygen. A 1000 mL bag of Hartmann's solution was infusing at a 12/24 rate. A metaraminol infusion was commenced shortly after arrival. Over the next 2 hours the patient remained hypotensive, with a SBP below 100 mm Hg. A urinary catheter was inserted with 220 mL of initial urine drainage. When the SBP dropped to 60 mm Hg metaraminol was bolused and the infusion rate increased to 4 mL (2.4 mg)/hr, followed by a 1000 mL stat bolus of CSL solution and another 1000 mL over the next 2 hours. Repeat Hb was 10.0 g/dL and Cr 123 umol/L.

At 2:00 pm a pressure bandage was applied to the patient's thigh, presumably because ongoing haemorrhage was suspected. INR was checked and found to be elevated at 1.7. Between 2:00 pm and 6:00 pm a total of 2 units of blood, followed by 2 units of FFP, and 8 units of cryoprecipitate were administered. Tranexamic acid and vitamin K were also given. The patient was anuric for 2 hours during this period. Jugular venous pressure was described as "significantly decreased" on a bedside ultrasound scan. At 3:00 pm the patient was taken for a CTA to look for active bleeding. Initial ICU notes indicated that the scan showed "extensive thigh/pelvis haematoma" with "no active bleeding point seen". Later, notes described "?minor extravasation ?bone fragment on delayed phase CTA". The final CTA result reported "appearances suggest active haemorrhage from a branch of the profunda femoris at the level of the lesser trochanter". BP improved during the afternoon, with SBPs >110 mm Hg from 2:40 pm onwards. Urine production recommenced at a rate of 15-40 mL/hr. By 5:00 pm the metaraminol infusion had been ceased, with SBP >130 mm Hg and MAP >70 mm Hg. In the evening runs of AF were noted. The patient was described as haemodynamically stable. Calcium gluconate and magnesium sulphate were administered. Atrial flutter was noted later in the evening. BP remained stable.

Day one postoperatively: Overnight the metaraminol infusion was recommenced for a BP of 95/40 mm Hg. Urine output slowed to 5-20 mL/hr. In the morning staff noted that the patient was confused, and in atrial flutter with 3:1 block. The Cr had increased to 171 umol/L and high sensitivity Troponin I level was elevated at 0.365 ug/L (normal range <0.056). Over the day 8 x 250 mL CSL fluid boluses were given for decreased urine output or MAP <60 mm Hg. Apart from one reading, SBP remained above 100 mm Hg on a metaraminol infusion. The patient remained in atrial flutter with the ventricular rate varying between 40-90 bpm. Warm peripheries were noted. BP was monitored using a non-invasive method after the arterial line was pulled out by the patient in the evening. At 10:30 pm the patient was described

as diaphoretic and cold peripherally. Rhythm was said to be atrial flutter at a low rate (in 40s on the observation chart) with a BP of 97/38. The metaraminol infusion was increased from 7 to 8 mg/hr. Oliguria persisted. A further bolus of 250 mL CSL solution was given on a background of CSL infusing at 125 mL/hr.

Day two postoperatively: Overnight, after an hour of anuria was noted, a decision was made to continue IV filling. The aramine infusion was running at 8 mL (4.8 mg)/hr at this time and the BP was 113/42 mm Hg. A further 3 x 250 mL boluses of fluid were given, with no sustained improvement in urine output. The patient was described as drowsy. The next morning tests revealed worsening renal function with a Cr of 294 $\mu\text{mol/L}$ and K^+ of 5.5 mmol/L. High Sensitivity-Troponin I had raised to 0.578 $\mu\text{g/L}$ (ref <0.056). INR was 1.8, WCC 19.8, and Hb 10.0 g/dL. Urine output did not improve with a 500 mL bolus of Albumex 4% or with boluses of IV frusemide (20 mg and 100 mg). Another dose of vitamin K was given. The pressure bandage was removed. At approximately 12:00 pm "Heart block/bradycardia" was noted, and this was unresponsive to atropine and adrenaline. Progression to an agonal rhythm occurred and the patient died.

The death was reported to the coroner. Acute renal failure was listed as the possible cause of death. It was noted that CPR had not been performed "in view of advanced age and poor prognosis". A subsequent summary of the clinical course by a physician described an "advance decision not to haemofilter given age".

Assessor's comments:

There was neither postmortem result nor a coronial investigation report available for review. Therapeutic interventions were generally well documented. However, it was difficult to follow the clinical decision-making processes in the postoperative period. For example: the patient had an unplanned admission to ICU from the recovery room after an elective total hip replacement operation, yet the decision to transfer the patient to ICU, and the reason for this escalation of care, were not documented in the anaesthetic record, operation or recovery room notes.

Subsequently, from review of later ICU notes, it became apparent that surgery had been complicated by a femur fracture and bleeding, with bleeding continuing into the postoperative period. In ICU the patient developed evidence of progressively worsening acute kidney injury, with increased creatinine, oliguria and hyperkalaemia. At some point in the perioperative period a decision was made not to haemofilter the patient. This decision was not documented until after the patient's death when it was noted in a letter summarising the patient's hospital admission.

Opportunities for improvement:

- Contemporaneous documentation of significant clinical management decisions in the medical record, particularly when a patient's condition deteriorates or care requirements change.
- The question was raised as to whether a Thallium-Persantin scan should have been performed as part of the preoperative assessment. The current 2014 ACC/AHA guideline on perioperative cardiovascular evaluation and management of patients undergoing noncardiac surgery recommends non-invasive pharmacological stress

testing for patients with elevated risk and poor or unknown functional capacity only if it will change management.⁽⁶⁾ In this case the physician commented that evidence of an inferior infarct on a preoperative echocardiogram would not have precluded surgery.

- Regarding conduct of anaesthesia: total IV anaesthesia is a well-recognised anaesthetic technique for total hip replacement. No major anaesthetic problems were noted intraoperatively. Ephedrine and metaraminol were given towards the end of the procedure, with SBPs maintained above 100 mm Hg. The reason for arterial line insertion at the end of the case was not documented on the anaesthetic record. Presumably close postoperative haemodynamic monitoring was felt to be warranted, and transfer to ICU was planned.
- Regarding management in the recovery room: Inadequate response to hypotension. The only documented haemodynamic intervention was a single 250 mL bolus of HES solution. The background CSL infusion had been ordered at a rate of 1000 mL over 12 hours. No vasopressors were administered. There were no documented discussions with or reviews by medical staff in the recovery room notes. Redaction of names from the IV fluid orders rendered it unclear as to who ordered the HES solution. SBP ranged between 80-105 mm Hg in the recovery room. On arrival in ICU from the recovery room the patient's BP was 82/33 mm Hg.

Subsequently, in ICU, the patient's haemodynamic parameters improved in response to vasopressors and significant fluid replacement therapy. This was more than 3 hours after hypotension was first documented.

Hypotension is one of the few modifiable risk factors for postoperative acute kidney injury, and hypovolaemia due to bleeding is an immediately treatable cause of hypotension. Earlier and more aggressive IV fluid replacement therapy in the recovery room may have reduced the degree and/or duration of postoperative hypotension. If more complete haemostasis could have been achieved at this point the outcome might have been improved.

- Determination of an adequate postoperative MAP target to avoid potentially compromising end organ perfusion needs to take into account the individual patient's specific clinical circumstances and their known preoperative BP.

This patient had treated hypertension, with a preadmission BP of 140/80 mm Hg (MAP 100 mm Hg). Although hypotension is a well-recognised risk factor for postoperative complications such as acute kidney injury and myocardial ischaemia, there is no clear consensus on how hypotension should be defined.⁽⁷⁾ It is difficult to find evidence in the literature for an optimal target MAP value outside of articles describing management of sepsis. However, a SBP >100 mm Hg and a MAP of 70 mm Hg would be commonly accepted haemodynamic goals for elderly patients.

Area for consideration: Balance between vasopressor use and fluid replacement therapy. Maintenance of normal renal perfusion is important in prophylaxis against postoperative acute kidney injury.^(8, 9) In this patient, hypovolaemia due to ongoing bleeding appeared to be the major contributing factor to early postoperative hypotension. On arrival in ICU the patient's BP was 82/33 mm Hg. Initial management involved administration of a vasopressor infusion to raise MAP towards a target of 70 mm Hg. At this time IV fluids were running at a rate of only 85 mL/hr. More aggressive fluid replacement did not commence until an hour after arrival when the patient's SBP dropped to 60 mm Hg. Only then did the patient's haemodynamic status and urine output start to improve, and it was another hour before

SBPs above 100 mm Hg were sustained. While vasopressors have a role in hypovolaemic shock in rapidly raising MAP to maintain end organ perfusion, it is a bridging manoeuvre that enables the treating team to catch up with fluid replacement for the volume deficit.

- Regarding cardiac rhythm: commenting on whether the patient was in complete heart block on day one postoperatively. The only ECG available for review from that day was taken at 8:20 am. The rhythm on this ECG does not look like coronary heart blockage: the ventricular rhythm appears to be atrially driven, with each QRS complex preceded by atrial activity with a consistent PR interval. It is not clear whether the rhythm is atrial flutter, as the atrial activity does not look like typical flutter waves. In further support of the rhythm not being complete heart block, the ventricular rate is 51 bpm on the ECG, and the morphology of the QRS complexes is similar to that on the preoperative ECG. It is noteworthy that the patient's BP was >120/40 mm Hg around the time the ECG was taken.

Area for consideration: Possible contribution of arrhythmias and/or myocardial injury to ongoing hypotension. On the evening of day one postoperatively nursing staff noted runs of AF and subsequently of atrial flutter with variable block. The troponin I level also rose over postoperative days one and two, raising the possibility of myocardial injury. It is possible that these arrhythmias and/or underlying myocardial injury were contributing to ongoing difficulty in maintaining haemodynamic stability. It would be helpful to know whether evidence of myocardial injury was identified at postmortem examination.

By the time the patient was said to have developed "heart block/severe bradycardia" on day two postoperatively, worsening renal function with oliguria and hyperkalaemia were evident. Subsequent notes indicate that by that time a decision had been made not to haemofilter the patient. In such circumstances it would seem unlikely that temporary pacing would have changed the overall outcome.

At the age of 91 this patient certainly had limited physiological reserves to deal with any major perioperative complication. However, the chances of a positive perioperative outcome may have been greater if it had been possible to correct the postoperative hypovolaemia due to bleeding more quickly and thoroughly.

If there was active bleeding, and it was possible to achieve more complete haemostasis, then that should have been an urgent priority. If haemostasis could not be improved then earlier restoration of normovolaemia using IV fluids may have improved the chances of a positive perioperative outcome.

Surgical lessons:

This case illustrates the concerns about choice of approach for what was probably a straight forward case. We do not know whether the surgeon had extensive experience of an anterior approach. This patient sustained significant complications with a fractured femur, a fractured acetabulum and an arterial injury to profunda femoris. These complications are more likely to occur when the surgeon is unfamiliar with the approach. When performing surgery through an approach with which you are unfamiliar you should have a low threshold to convert to an approach with which you are more familiar to deal with unexpected complications.

References

6. Fleisher L, Fleischmann K, Auerbach A, Barnason S, Beckman J, Bozkurt B, et al. 2014 ACC/AHA guideline on perioperative cardiovascular evaluation and management of patients undergoing noncardiac surgery: a report of the American College of Cardiology/American Heart Association Task Force on practice guidelines. *J Am Coll Cardiol* [Internet]. 2014 [cited 2016 Jun 14];64(22):e77-137. Available from: http://ac.els-cdn.com/S0735109714055363/1-s2.0-S-main.pdf?_tid=d3ab0c2e-31eb-11e6-8cfc-00000aacb362&acdnat=1465880142_c87f7c153605c5b175990bd643a56e53.
7. Walsh M, Devereaux PJ, Garg AX, Kurz A, Turan A, Rodseth RN, et al. Relationship between intraoperative mean arterial pressure and clinical outcomes after noncardiac surgery: toward an empirical definition of hypotension. *Anesthesiology* [Internet]. 2013 [cited 2016 Jul 12];119(3):507-15. Available from: <http://anesthesiology.pubs.asahq.org/article.aspx?articleid=1918179>.
8. Calvert S, Shaw A. Perioperative acute kidney injury. *Perioper Med (Lond)*. 2012;1:6.
9. Abuelo J. Normotensive ischemic acute renal failure. *N Engl J Med*. 2007 Aug 23;357(8):797-805.



Orthopaedic/Vascular/Neuroradiology

Case 12: Intracerebral embolus after fractured fibula due to paradoxical embolus without thromboprophylaxis

Clinical details:

A 35-year-old patient with no significant comorbidities tripped and broke their fibula while overseas. The patient was placed in back slab and flown back to Australia.

An operation with open reduction internal fixation and bone graft was performed in a private hospital 16 days after the event. There was intraoperative instability due to a possible PE SBP down to 40-50 mm Hg). The patient was taken to the post-anaesthesia care unit and was initially fine on waking; however, after 15 minutes became hemiplegic. The diagnosis was a right cerebral infarct from paradoxical embolus though the patient was not known to have a patent foramen ovale prior to this.

The patient was transferred to a public institution for attempted middle cerebral artery clot retrieval, complicated by iatrogenic external iliac artery injury (femoral artery “shredded” from ProGlide closure device) requiring emergency vascular repair with vein patch. Found to have high puncture with passage of puncture through inguinal ligament. The postoperative course was characterised by poor neurological function and eventual brain death. Organ donation was performed.

Assessor’s comments:

Limited notes were supplied for the initial open reduction and internal fixation. Intraoperative anaesthetic notes show that no heparin was given although a tourniquet was used. No notes were available regarding the preoperative use of heparin or similar. The surgeon’s operation note does not state any postoperative orders for DVT prophylaxis. There were no inpatient or postoperative notes from the surgeon. Therefore, no comment can be made about the first-line assessor’s question about whether DVT was considered after a long haul flight and use of a back slab.

The outcome was very unfortunate. The glaring omission was the lack of confirmation of DVT prophylaxis administration. The lack of use of preoperative heparin was not able to be determined; however, as it was not charted on the supplied drug chart it is unlikely that it was given.

The usefulness of ultrasound for vascular punctures should be highlighted, particularly in the prevention of inadvertent malpuncture. It was not recorded whether or not this was used. The passage of a sheath through the inguinal ligament is usually detectable and should be recognised due to the increased resistance.

Surgical lessons:

There was no record of whether DVT prophylaxis was given while the patient awaited surgery. This case highlights the importance of DVT prophylaxis in patients having delayed surgery after trauma, even in young patients with mild to moderate injuries.

Paediatric Surgery

Case 13: Misdiagnosis of Hirschsprung's disease

Clinical details:

The patient presented to hospital over several days with abdominal distention and constipation. Then the patient re-presented at which time a cardiac arrest occurred. The patient was resuscitated and transferred to another hospital's ICU. Past history was initially not known, but 2 days after delivery had been admitted to the neonatal ward with failure to pass meconium. Rectal biopsy was negative and spontaneous bowel function improved. These details were unknown at first because the child was admitted as a baby under a different name and unique record.

Once this was appreciated the diagnosis changed from "bowel obstruction/volvulus" to "toxic megacolon in ? Hirschsprung's disease". Immediate laparotomy confirmed toxic megacolon (treatment decompression and ileostomy) and frozen sections confirmed distal colonic Hirschsprung's disease. A repeat laparotomy was performed 1 to 2 days later because of recurrent abdominal distention and the bowel externalised in a plastic bag. Deterioration continued resulting in a second laparotomy with excision of necrotic externalised bowel. Deterioration continued until death 6 days after admission despite all efforts at resuscitation.

Assessor's comments:

This five-month-old presented to the local ED with abdominal distension, in extremis. The baby required CPR, intubation and ventilation before transfer to a tertiary centre. The baby had initially been investigated as a neonate for abdominal distension and constipation, with a rectal suction biopsy which was interpreted as being unlikely to represent Hirschsprung's disease. On arrival at the tertiary hospital the baby continued to be resuscitated and a laparotomy was performed.

The findings were consistent with Hirschsprung's disease with a sigmoid colon transition zone. Biopsies were taken and an ileostomy formed. The following day a second laparotomy and silo formation was performed for abdominal compartment syndrome. The bowel perfusion improved on delivery from the abdomen.

The baby remained critically ill over the following days, with the visible bowel in the silo showing signs of necrosis. On day five a further laparotomy was performed with resection of the majority of small bowel. This left 50 cm of small intestine of which only 25 cm looked healthy. Despite continued intensive management the decision to withdraw care was made the following day because of continuing deterioration and multiorgan failure.

There is no question that the medical care during the final admission was of a high standard. The main concern is related to the interpretation of the rectal biopsy done in the neonatal period. There are considered to be two criteria for excluding Hirschsprung's disease on rectal biopsy. The initial biopsy fulfils only one of these. Therefore the biopsy sample was small it was difficult to comment on whether the lack of ganglion cells on microscopy was significant. The pathologist's report was ambiguous, stating that the biopsy was normal but did not exclude Hirschsprung's disease. The baby stooled spontaneously over the subsequent

few days while still an inpatient, the biopsy was not repeated and the baby discharged. No surgical follow-up was arranged.

The second concern is the discharge from the referring ED the previous evening. The notes were not available so no comment can be made on whether the clinical condition at that time warrants criticism. The clinical deterioration with Hirschsprung's enterocolitis can be rapid, but if Hirschsprung's disease had been 'excluded' it would not feature in the differential diagnosis. The degree of problems with constipation between admissions was not clear although the baby was on laxatives and on/off constipation is mentioned in the clinical notes.

There are a number of preventative measures that can be taken:

Pathology report: The diagnosis of Hirschsprung's disease should only be excluded on the presence of ganglion cells on the rectal suction biopsy. In this case, where a normal acetylcholine esterase stain is seen, the pathologist's report should clearly state that Hirschsprung's disease cannot be excluded.

Communication of pathology result: It is not clear from the neonatal admission as to how and to whom the biopsy result was conveyed. Most importantly, whether the biopsy was conveyed verbally as 'normal' within the surgical team and the details of the result not discussed. This relates to the facts of the biopsy (no ganglion cells seen) and the interpretation (normal).

Repeat of rectal biopsy: In this case the assumption has been made that the biopsy result and the clinical progress of the baby did not warrant a repeat biopsy. It is not uncommon for babies with Hirschsprung's disease to stool well for a period of time following rectal instrumentation (rectal washouts & biopsy). In a baby with a textbook presentation of Hirschsprung's disease and a non-diagnostic biopsy it should have been repeated.

Follow-up: If this baby had been followed up in a paediatric surgical clinic with ongoing problems with constipation there is a good chance that the biopsy result would have been reviewed and the biopsy repeated.

Communication: This is a particular problem on neonatal units. Because the primary carers in most of these units are the neonatologists, the discharge counselling is not performed by surgeons. Paradoxically, a baby with a similar presentation who is on the paediatric surgical ward would be unlikely to escape without clear instructions to the family about what to do in the event of ongoing problems and would be more likely to have paediatric surgical follow-up.

Surgical lessons:

The key to this case is the interpretation of the rectal suction biopsy, as outlined by the second-line assessor, and the clinical course of the patient. All the points raised are reasonable and this is a very timely case to be reported for the information of all paediatric surgeons.

Urology

Case 14: Septic shock with delay in relief of urinary obstruction

Clinical details:

An 84-year-old man was transferred with acute renal failure (creatinine 350 umol/L). He had frail general health with issues including chronic obstructive airways disease, diverticulitis, UTIs and a previous left below-knee amputation. He had a known history of transitional cell carcinoma of the bladder and had undergone a recent cystoscopy prior to admission. There was an implication that this was muscle invasive disease although there was no pathology to confirm this. There was no information provided or apparent in the notes, about events prior to this admission. A CT scan on admission demonstrated bilateral hydronephrosis with an obstructed left system due to a large distal ureteric calculus, and obstructed right system of uncertain cause, possibly related to his known carcinoma of the bladder.

An attempt was made to gain access to both ureters in a retrograde fashion but failed due to technical reasons. It was unclear whether this procedure was performed by a consultant urologist or trainee. Bilateral nephrostomies and antegrade JJ stents were inserted over the subsequent 3 weeks of his admission. He ultimately died of multiorgan failure.

Assessor's comments:

The case notes were reasonably adequate. More information about the events leading to this admission would have been helpful, such as details of the original cystoscopy and confirmation of the underlying pathology. Most of the doctor's entries into the notes failed to include the time of the entry, leading to possible confusion. This is an area which requires improvement. There was no reference to any consultant urologist input throughout the case.

The patient had problems with fluid balance issues throughout the admission. After the insertion of the right nephrostomy tube the resident medical staff seemed to fail to understand the significance of the poor urine output through the nephrostomy tube. It was not until 2 days later that the first medical note was made about this issue. There was no indication that the medical staff understood the significance of this in the context of a man with acute renal failure. It took a further 4 days for this to be addressed via the insertion of an antegrade JJ stent.

The resident's assessments and responses to the patient's poor urine output were of variable quality, with some being substandard. The fluid charts would suggest that the patient was in a significant positive fluid balance throughout the admission and this was not commented on. It was over two weeks after his presentation before any attempt was made to disobstruct his left kidney.

There were significant delays between the noting of issues and performing required procedures. In a frail elderly man with multiple comorbidities these delays could almost certainly have contributed to his ultimate demise. Some examples of areas of concern include:

- Although he was admitted with acute renal failure and evidence of bilateral ureteric obstruction, it took 48 hours from the time of his admission until his original procedure was performed. In my opinion this delay was excessive.
- It may have been more advisable to place a nephrostomy in the left rather than the right kidney. It is likely that this would have been the best preserved kidney given the history of an obstructing calculus compared with likely malignant obstruction of the right kidney. No notes were made discussing the rationale for placing the initial nephrostomy tube in the right kidney.
- It took 48 hours for the medical staff to note that the nephrostomy tube was not draining. The implications of this in terms of either a misplaced nephrostomy tube (i.e. not in the collecting system) or reflecting very poor function from that kidney were never expressed and possibly not understood by the medical staff. It was not until nearly a week later that an antegrade JJ stent was inserted.
- Most of the notes were made by junior residents, often the covering doctor. There was no clear evidence of consultant urologist input throughout the case.
- His general condition continued to deteriorate and no attempt was made to disobstruct the left ureter until some 18 days after admission.

The quality of care received by this patient was inadequate. Given his considerable comorbidities there was only ever going to be a short window of opportunity to reverse his obstructed kidneys and offer him the best chance of survival. It took over two weeks to disobstruct both ureters by which time multiorgan failure had set in and there was little chance of reversing his medical conditions. More timely intervention may have altered the outcome. There was no evidence of consultant urologist input.

These comments must be taken in the context of an elderly man with multiple comorbidities and possibly an advanced malignancy (although absolute evidence for that was not provided in the notes).

Surgical lessons:

This case has clearly demonstrated areas of concern, as enunciated by the second-line assessor's report. Based on the information provided this patient's management was substandard, and this highlights the importance of experienced consultant involvement. The decisions made by the presumed junior medical staff demonstrate their inexperience as well as a lack of direction in the absence of advice from a senior urologist.

Other areas of concern are the lack of reference to family consultations, and the underlying assumption that the patient was potentially more at risk because of his chronic obstructive airways disease, diverticulosis and UTIs. Many 84-year-old people cope fairly well with these conditions.

Vascular

Case 15: Delay in management of ischaemic leg; communication breakdown

Clinical details:

An elderly, previously independent patient was found chairbound and immobile in their private accommodation. According to the paramedics' notes the patient was alert but unable to weight-bear. The patient's lower limbs were painful and cold.

The patient was malnourished and had been neglecting themselves. The patient was a known sufferer of AF (not on warfarin), hypertensive and had COPD on a background of alcohol dependence.

On presentation to the ED at 8:24 pm the patient was assessed by the resident. The patient was later assessed by the surgical registrar (at 10:00 pm). The diagnosis of severe lower limb ischaemia was established. The duration of the symptoms was unknown. The ischaemia was more severe on the left side; both sensory and motor deficits were noted. The pathology tests revealed creatine kinase levels five times higher than normal. Renal function was acceptable and the patient was mildly anaemic. Duplex ultrasound revealed no flow in the right popliteal artery or calf, while on the left side no flow was seen below the common femoral artery.

A CTA at 3:00 am the next morning confirmed left common femoral artery occlusion and right popliteal artery occlusion in the background. In the evening the decision was made via a telephone call with the consultant that the patient needed left femoral thrombectomy to restore the arterial flow to the lower limb. IV hydration and heparin administration were commenced and observation continued until surgery the following morning.

The patient underwent left common femoral endarterectomy, thrombectomy and patch closure of the common femoral artery at 10:00 am for the mottled, insensate limb. Fasciotomies of all three leg compartments were also performed. The calf muscles were found non-viable during the procedure. The patient remained haemodynamically stable during the 3-hour procedure/anaesthesia.

The surgeon requested ICU/HDU admission in the postoperative instructions. While the patient was being managed in recovery oliguria was noted, and the patient's condition was regarded as critical. There was no clinical indication that the lower limb perfusion improved after revascularisation. According to the notes there was ongoing discussion about the indication for transferring the patient to the ICU.

Finally the patient was sent back to the ward where their "critical condition" rapidly deteriorated. The patient became hypotensive and was unresponsive to treatment (fluid resuscitation and inotropes). After the ensuing cardiac arrest CPR was unsuccessful.

Assessor's comments:

Potential delay: The patient was admitted to the ED with critical lower limb ischaemia. The duration of the ischaemic symptoms was unknown. After establishing the diagnosis by angiography there was a delay of about 10 hours before the patient was eventually taken to the operating theatre.

Preoperative assessment and management plan: The surgical admission notes appeared to be adequate and the preoperative diagnostic tests were organised without delay. Missing is the initial anaesthetic assessment regarding perioperative risk and plans for postoperative care (patients with comorbidities who face the potential systemic effects of revascularisation may need a higher level of care).

Postoperative care: Apparently the surgeon was aware of the potential postoperative difficulties therefore a request was made in the operating notes for ICU or HDU transfer. There was no record of direct communication between consultants (anaesthetist, intensivist and surgeon) addressing the issue of why the patient was denied ICU admission. The ICU registrar's notes clearly highlight the communication breakdown when he/she tried in vain to liaise between consultants.

Surgical lessons:

There was considerable delay in the management of this patient. The consultant did not physically see this patient until the next morning, and had made a decision to review the patient prior to surgery. Thus critical ischaemia was untreated with the resultant muscle necrosis and death of the patient. Primary amputation without revascularisation after noting the dead muscle at fasciotomy (or no surgery at all) might have been preferable in this patient, who had suffered bilateral embolic episodes of the legs. This patient would have had a better chance at survival (even if it were still slim) had there been better communication between the treating doctors and more considerate preoperative planning. Postoperative ICU admission would have been appropriate under the circumstances.

List of shortened forms

AF	atrial fibrillation
AVM	arteriovenous malformation
AV block	atrioventricular block
BMI	body mass index
BP	blood pressure
BPM	beats per minute
COPD	chronic obstructive pulmonary disease
CPR	cardiopulmonary resuscitation
Cr	Creatinine
CSL	Compound Sodium Lactate (solution)
CT	computed tomography
CTA	computed tomography angiogram
DVT	deep vein thrombosis
ECG	electrocardiogram
ED	emergency department
ERCP	endoscopic retrograde cholangiography and pancreatography
FFP	fresh frozen plasma
GCS	Glasgow Coma Scale
Hb	haemoglobin
HDU	high dependency unit
HES	hydroxylethyl starch (solution)
HR	heart rate
ICU	intensive care unit
INR	international normalised ratio
IV	intravenous
K	potassium
MAP	mean arterial pressure
MRI	magnetic resonance imaging
Na	sodium
NOF	neck of femur
PE	pulmonary embolus
SaO ₂	arterial oxygen saturation
SBP	systolic blood pressure
SCF	surgical case form
UTI	urinary tract infection
VASM	Victorian Audit Of Surgical Mortality

VASM Management Committee Members

Mr Barry Beiles	Clinical Director, VASM
Mr Trevor Jones	Chair, VSCC
Ms Vickie Veitch	Manager, Clinical Councils Unit, DHHS
Ms Hayley Hellinger	Senior Project Officer, Clinical Councils Unit, DHHS
Dr Rachael Knight	The Royal Australian and New Zealand College of Obstetricians and Gynaecologists
A/Prof Rodney Judson	General Surgeons Australia
Ms Andrea Kattula	The Australian and New Zealand College of Anaesthetists
Mr Jason Chuen	Chair, Victorian Regional Committee
Mr Russell Taylor	Australasian Association of Paediatric Surgery
Ms Lee Gruner	President, The Royal Australasian College of Medical Administrators
Mr Nigel Broughton	Australian Orthopaedic Association
Dr Jocelyn Shand	Dental Practice Board
Mr Patrick Lo	Neurosurgical Society of Australasia
Mr Douglas Druitt	Urological Society of Australia and New Zealand
Mr Adam Zimmet	Cardiothoracic Craft Group
Mr Ivan Kayne	Consumer Representative
Ms Claudia Retegan	Project Manager, VASM
Mr Gordon Guy	ANZASM Manager, Research, Audit & Academic Surgery Division

References

1. Lorusso R, Mariscalco G, Vizzardi E, Bonadei I, Renzulli A, Gelsomino S. Acute bowel ischemia after heart operations. *Ann Thorac Surg.* 2014 Jun;97(6):2219-27.
2. Barnard J, Millner R. A review of topical hemostatic agents for use in cardiac surgery. *Ann Thorac Surg.* 2009;88(4):1377-83.
3. Pu L, Singh R, Loong C, de Moura E. Malignant Biliary Obstruction: Evidence for Best Practice. *Gastroenterol Res Pract* [serial on the Internet]. 2016 11 May 2016]: Available from: <http://www.hindawi.com/journals/grp/2016/3296801/>.
4. Clough A, Hamill D, Jackson S, Remilton M, Eyre R, Callahan R. Outcome of three common bariatric procedures in the public sector. *ANZ J Surg.* 2016 Apr 12 doi: 10.1111/ans.13585. [Epub ahead of print].
5. Arteaga-Gonzalez I, Martin-Malagon A, Martin-Perez J, Carrillo-Pallares A. Usefulness of Clinical Signs and Diagnostic Tests for Suspected Leaks in Bariatric Surgery. *Obes Surg.* 2015 Sep;25(9):1680-4.
6. Fleisher L, Fleischmann K, Auerbach A, Barnason S, Beckman J, Bozkurt B, et al. 2014 ACC/AHA guideline on perioperative cardiovascular evaluation and management of patients undergoing non-cardiac surgery: a report of the American College of Cardiology/American Heart Association Task Force on practice guidelines. *J Am Coll Cardiol* [Internet]. 2014 [cited 2016 Jun 14];64(22):e77-137. Available from: http://ac.els-cdn.com/S0735109714055363/1-s2.0-S-main.pdf?_tid=d3ab0c2e-31eb-11e6-8cfc-0000aacb362&acdnat=1465880142_c87f7c153605c5b175990bd643a56e53.
7. Walsh M, Devereaux PJ, Garg AX, Kurz A, Turan A, Rodseth RN, et al. Relationship between intraoperative mean arterial pressure and clinical outcomes after noncardiac surgery: toward an empirical definition of hypotension. *Anesthesiology* [Internet]. 2013 [cited 2016 Jul 12];119(3):507-15. Available from: <http://anesthesiology.pubs.asahq.org/article.aspx?articleid=1918179>.
8. Calvert S, Shaw A. Perioperative acute kidney injury. *Perioper Med* (Lond). 2012;1:6.
9. Abuelo J. Normotensive ischemic acute renal failure. *N Engl J Med.* 2007 Aug 23;357(8):797-805.

NOTES

Contact details

Victorian Audit of Surgical Mortality (VASM)
Royal Australasian College Of Surgeons
College of Surgeons' Gardens
250–290 Spring Street
East Melbourne VIC 3002 Australia

Web: www.surgeons.org/vasm
Email: vasm@surgeons.org
Telephone: +61 3 9249 1153
Facsimile: +61 3 9249 1130

Postal address:
Victorian Audit of Surgical Mortality (VASM)
GPO Box 2821
Melbourne VIC 3001 Australia

The information contained in this case note review booklet has been prepared by the Royal Australasian College of Surgeons Victorian Audit of Surgical Mortality Management Committee, which is a declared quality improvement activity. The Australian and New Zealand Audit of Surgical Mortality, including the Victorian Audit of Surgical Mortality, also have protection under the Commonwealth Qualified Privilege Scheme under Part VC of the Health Insurance Act 1973.

